

## Chronic Disseminated *Trichosporon asahii* Infection in a Leukemic Child

M. H. Meyer,<sup>1</sup> V. Letscher-Bru,<sup>1</sup> J. Waller,<sup>1</sup> P. Lutz,<sup>2</sup> L. Marcellin,<sup>3</sup> and R. Herbrecht<sup>4</sup>

<sup>1</sup>Institut de Parasitologie et de Pathologie Tropicale, Faculté de Médecine, Services <sup>2</sup>d'Onco-hématologie Pédiatrique and <sup>3</sup>d'Anatomie Pathologique Générale, and <sup>4</sup>Département d'Hématologie et d'Oncologie, Hôpital de Hautepierre, Strasbourg, France

**We report a case of chronic disseminated *Trichosporon asahii* infection in a leukemic child. Administration of amphotericin B lipid complex resulted in rapid control and improvement of the initial infection but failed to prevent the development of chronic disseminated disease. Cure was achieved after treatment was changed to a 20-month course of itraconazole. This case report demonstrates that *Trichosporon* species can cause chronic disseminated disease with a pattern similar to that of disease caused by *Candida* species.**

*Trichosporon* infections are an increasingly common complication of neutropenia and other conditions associated with severe immunocompromise. The outcome of disseminated *Trichosporon* infection most often is poor, and the fatality rate is >70% [1, 2].

Recently, the genus *Trichosporon* was taxonomically revised [3]. Generally, 2 species have been associated with invasive infections in humans: *Trichosporon beigelii* and *Trichosporon capitatum* [2]. *T. capitatum* has now been reclassified as *Geotrichum capitatum* or *Blastoschizomyces capitatus*. *T. beigelii* (which was previously accepted as being identical to *Trichosporon cutaneum*) now corresponds to 6 different species. Invasive *Trichosporon* infections are due to *Trichosporon asahii* in most cases and to *Trichosporon mucoides* and *Trichosporon inkin* (formerly called "*Sarcinosporon inkin*") in a few cases.

Chronic disseminated candidiasis is a well-known complication of candidemia in neutropenic patients [4]. A similar

chronic evolution of *Trichosporon* infection has not yet been reported. We describe a case of *T. asahii* fungemia in a leukemic child. The initial presentation was severe and was successfully controlled by administration of amphotericin B lipid complex (ABLC). Nevertheless, this therapy could not prevent the occurrence of a chronic disseminated infection, with multiple hepatic and splenic abscesses, that evolved over the course of several months before cure was achieved with administration of oral itraconazole.

**Case report.** A 13-year-old child (weight, 55 kg) suspected of having acute leukemia was referred to the pediatric oncology department (Hautepierre Hospital, Strasbourg, France). A full blood count revealed anemia (hemoglobin level, 52 g/L), hyperleukocytosis (leukocyte count,  $55 \times 10^3$  leukocytes/ $\mu$ L), mild neutropenia (neutrophil count, 1380 neutrophils/ $\mu$ L), circulating blasts ( $45 \times 10^3$  blasts/ $\mu$ L), and thrombocytopenia (platelet count,  $86 \times 10^3$  platelets/ $\mu$ L). Examination of bone marrow confirmed the diagnosis of acute biphenotypic leukemia. Induction chemotherapy with cytarabine, idarubicin, and etoposide was initiated.

Three days after initiation of chemotherapy, the patient became severely neutropenic (neutrophil count, 460 neutrophils/ $\mu$ L) and febrile. Results of fungal and bacterial cultures of blood samples were negative. Broad-spectrum antibiotic therapy combining vancomycin, ceftazidime, and amikacin was started. The fever persisted, and low-dose intravenous amphotericin B (25 mg/day [0.45 mg/kg/day]) therapy was introduced 8 days after the initiation of chemotherapy.

Despite the administration of empiric antifungal treatment, cultures of 3 blood samples obtained 10 (2 samples) and 11 (1 sample) days after initiation of amphotericin B therapy yielded yeasts later identified as *T. asahii*. The amphotericin B dosage was increased to 50 mg/day (0.91 mg/kg/day) for 2 days and, finally, to 75 mg/day (1.36 mg/kg/day), with the addition of 5-fluorocytosine (136 mg/kg/day), as the patient's clinical condition worsened.

Disseminated purpuric papules compatible with hematogenous dissemination of the fungal infection appeared despite administration of antifungal therapy. The patient's condition suddenly deteriorated, and septic shock with anuria and respiratory distress syndrome developed. At this time, the patient had diffuse pulmonary rales, bilateral pleural effusion, ascites, and metabolic acidosis. Laboratory investigations confirmed that acute renal failure had occurred (serum creatinine level, 252  $\mu$ M). The patient was transferred to the pediatric intensive care unit. The patient's Acute Physiology and Chronic Health

Received 21 December 2001; revised 20 February 2002; electronically published 13 June 2002.

Reprints or correspondence: Raoul Herbrecht, Département d'Hématologie et d'Oncologie, Hôpital de Hautepierre, Avenue Molière, 67098 Strasbourg, France (raoul.herbrecht@chru-strasbourg.fr); or Valérie Letscher-Bru, Institut de Parasitologie et de Pathologie Tropicale, 3 rue Koeberlé, 67000 Strasbourg, France (valerie.letscher@medecine.u-strasbg.fr).

**Clinical Infectious Diseases** 2002;35:e22-5

© 2002 by the Infectious Diseases Society of America. All rights reserved.  
1058-4838/2002/3502-00E3\$15.00

Evaluation II score was 25. Systolic blood pressure fell to 77 mm Hg, and inotropic support was required. The patient was not intubated but received oxygen at 100%.

The antifungal treatment regimen was changed to a daily dose of 200 mg (3.6 mg/kg) of ABLC. The patient's condition gradually improved: diuresis recovered 1 day after initiation of ABLC treatment, inotropic support was discontinued within 5 days, respiratory function improved significantly and the serum creatinine level normalized within 6 days, and skin lesions disappeared within 8 days. The patient recovered from neutropenia 9 days after initiation of ABLC therapy. The fever persisted for 17 days.

Although the patient's condition improved, mild fever reappeared 4 weeks after the initiation of ABLC therapy, followed a few days later by the onset of abdominal pain and hepatomegaly. An abdominal ultrasound and CT revealed multiple hepatic abscesses and splenomegaly, which suggested that a fungal infection might be present (figure 1). A percutaneous liver biopsy was performed, but the microscopic examination showed no abnormalities, and the results of mycologic cultures of biopsy specimens were negative. Administration of itraconazole capsules (400 mg/day) was started, and ABLC therapy was stopped. The patient had received a total dose of 9.6 g of ABLC over the course of 48 days.

Because serum levels of itraconazole were insufficient (peak levels: itraconazole, 58 ng/mL; hydroxyitraconazole, 85 ng/mL), the capsules were replaced by an oral suspension at the same daily dose. This led to a substantial increase in serum levels (peak levels: itraconazole, 1349 ng/mL; hydroxyitraconazole,

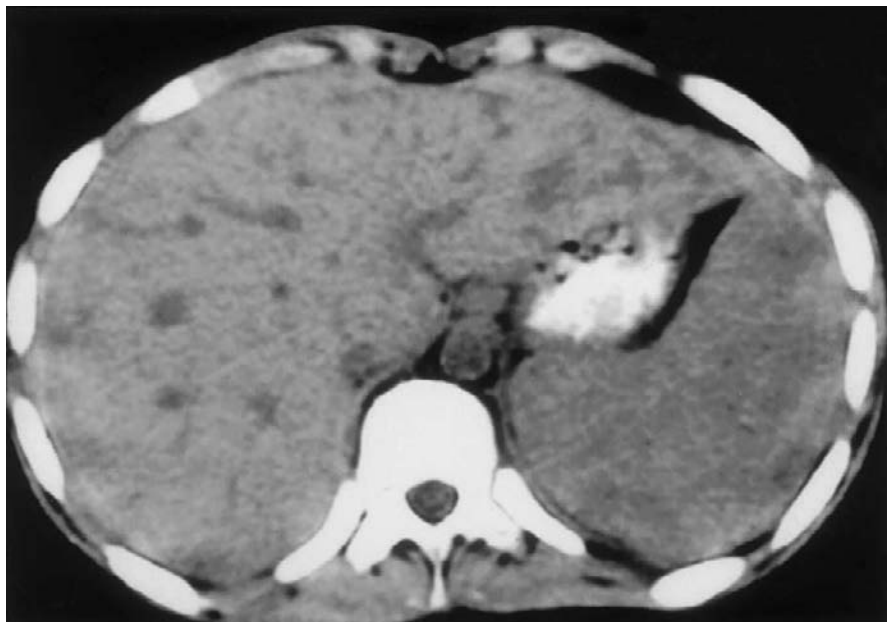
1998 ng/mL) and an improvement in the patient's condition. Fever and abdominal pain disappeared. An abdominal CT done after 4 months of itraconazole therapy showed the persistence of splenomegaly without any visible abscesses in the liver.

Splenectomy was considered. Laparoscopic examination revealed several tiny abscesses on the surface of the liver and adhesions between the liver and adjacent structures. A biopsy of one of these abscesses was performed. Periodic acid–Schiff staining of the liver biopsy specimen showed a well-structured granuloma without any visible fungal element. Gomori–methenamine silver staining demonstrated numerous hyphae inside the granuloma (figure 2). The results of mycologic cultures were negative.

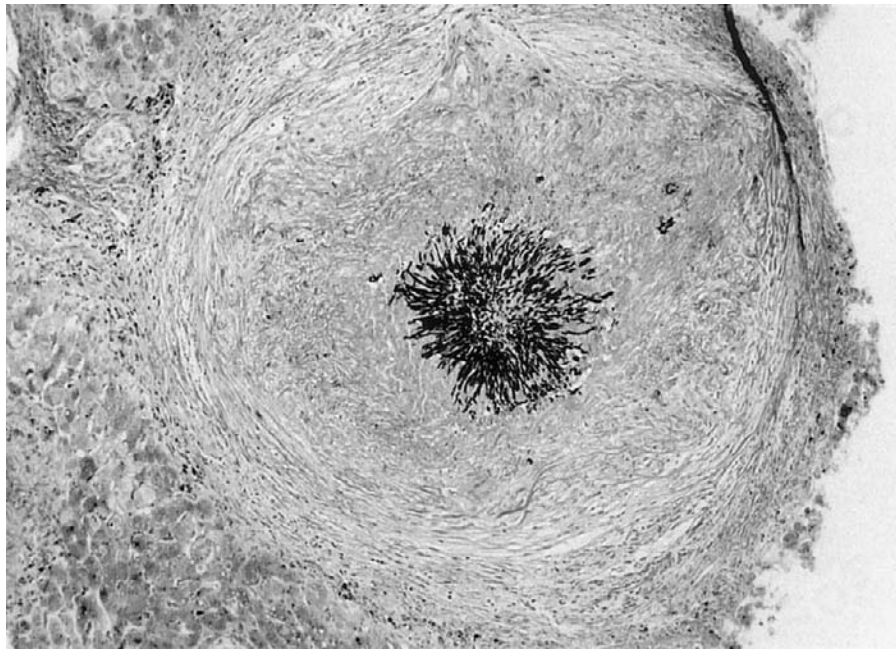
Treatment with oral itraconazole was continued for a total of 20 months while new cycles of antileukemic chemotherapy were initiated. Three years after the onset of the fungal infection, the patient was alive and in complete remission from leukemia. There was no evidence of persistent *Trichosporon* infection, and no abnormalities were seen on abdominal CT scans. No control liver biopsy was performed.

**Mycologic findings.** Three blood samples cultured on fungal medium (Mycosis-IC/F; Becton Dickinson) on 2 subsequent days (10 and 11 days after initiation of the first course of amphotericin B therapy) yielded yeasts after 2 days of incubation at 35°C in the Bactec NR 860 system (Becton Dickinson). The isolates from the patient's blood were identified morphologically and physiologically as *T. asahii*, on the basis of the revision of the genus *Trichosporon* by Guého et al. [3].

Each isolate was subcultured on Sabouraud glucose agar at



**Figure 1.** Abdominal CT scan showed heterogeneous spleen enlargement and multiple abscesses in the left lobe of the liver of a child with acute leukemia and *Trichosporon* infection.



**Figure 2.** Histopathologic examination of a laparoscopy-guided liver biopsy specimen from a child with acute leukemia and *Trichosporon* infection showed numerous hyphae surrounded by a granuloma (Gomori–methenamine silver stain; original magnification,  $\times 40$ ).

37°C for 48 h to allow further study of the morphology of the colonies, which appeared dry with a white farinose covering and a submerged margin. Morphology was studied microscopically, using slide cultures on potato-carrot-bile medium after incubation at 27°C for 48 h. Those slides showed typical *Trichosporon* hyphae breaking down into regular arthroconidia. Assimilative capacities were tested using the ID 32 C strip (bioMérieux), and the results were consistent with the identification of the isolate as *T. asahii*. MICs for amphotericin B, fluconazole, and itraconazole, measured using the Etest method (AB Biodisk), were 0.032, 2, and 2  $\mu\text{g/mL}$ , respectively.

**Discussion.** Invasive infections caused by *Trichosporon* species are a rare but potentially fatal complication of the immunosuppression associated with treatment of cancer [1, 2]. Successful treatment of *Trichosporon* infection is usually related to a rapid recovery from neutropenia.

Our case report is notable for the biphasic evolution of the infection. First, the patient developed a particularly severe acute phase, with septic shock and obvious signs of dissemination. ABLC rapidly controlled this acute phase, and resolution of septic shock, recovery from renal failure, and a decrease in the size and number of skin lesions occurred before the patient recovered from neutropenia. Nevertheless, ABLC failed to prevent the occurrence of chronic disseminated disease.

Chronic disseminated infection following candidemia results in the development of numerous abscesses in the liver, the spleen, and, sometimes, the kidneys. It is a common disease among leukemic patients but has not yet been reported in

association with *Trichosporon* fungemia. *Trichosporon* infections are less common than candidemia. They are often fatal during the acute phase, and, in most cases, chronic infection does not have time to develop. Our case report may reflect the relative refractoriness of *T. asahii* to amphotericin B therapy; fungemia occurred in spite of administration of amphotericin B deoxycholate therapy, and ABLC could not prevent the development of chronic visceral disease. In our case, the MIC for amphotericin B was low, but we did not evaluate fungicidal activity. In a report by Walsh et al. [5], the minimum lethal concentrations of amphotericin B were substantially higher than the MICs. In that study, most of the strains were inhibited, but not killed, by amphotericin B concentrations that can be safely achieved in serum with administration of deoxycholate amphotericin B in clinical practice. Use of ABLC does not result in higher serum concentrations than use of amphotericin B deoxycholate but should lead to significantly higher tissue concentrations, especially in the liver and the spleen [6, 7].

Experimental data suggest that azoles may be more appropriate for treatment of trichosporonosis [8, 9]. Most in vitro studies show that the MICs for itraconazole are lower than those for fluconazole among *Trichosporon* species, but no experimental or clinical evidence has shown that the efficacy of itraconazole is greater than that of fluconazole for treatment of *Trichosporon* infections [10, 11]. In our patient, substitution of itraconazole for ABLC clearly led to clinical improvement as soon as itraconazole serum levels were in the therapeutic range.

This case report demonstrates that *Trichosporon* species, like *Candida* species, can cause chronic disseminated disease. Although ABLC was effective against the acute phase of the disease, follow-up therapy with an azole was required to cure chronic lesions.

### Acknowledgment

We thank Shanti Natarajan-Amé for reviewing this manuscript.

### References

1. Walsh TJ, Melcher GP, Lee JW, Pizzo PA. Infections due to *Trichosporon* species: new concepts in mycology, pathogenesis, diagnosis and treatment. *Curr Top Med Mycol* **1993**; 5:79–113.
2. Herbrecht R, Koenig H, Waller J, Liu KL, Guého E. *Trichosporon* infections: clinical manifestations and treatment. *J Mycol Med* **1993**; 3: 129–36.
3. Guého E, Smith MT, de Hoog GS, Billon-Grand G, Christen R, Batenburg-van der Vegte WH. Contributions to a revision of the genus *Trichosporon*. *Antonie Van Leeuwenhoek* **1992**; 61:289–316.
4. Marr KA, Bowden RA. Fungal infections in patients undergoing blood and marrow transplantation. *Transpl Infect Dis* **1999**; 1:237–46.
5. Walsh TJ, Melcher GP, Rinaldi MG, et al. *Trichosporon beigeli*, an emerging pathogen resistant to amphotericin B. *J Clin Microbiol* **1990**; 28:1616–22.
6. Tiphine M, Letscher-Bru V, Herbrecht R. Amphotericin B and its new formulations: pharmacologic characteristics, clinical efficacy, and tolerability. *Transpl Infect Dis* **1999**; 1:273–83.
7. Wong-Beringer A, Jacobs RA, Guglielmo BJ. Lipid formulations of amphotericin B: clinical efficacy and toxicities. *Clin Infect Dis* **1998**; 27:603–18.
8. Anaissie E, Gokaslan A, Hachem R, et al. Azole therapy for trichosporonosis: clinical evaluation of eight patients, experimental therapy for murine infection, and review. *Clin Infect Dis* **1992**; 15:781–7.
9. Anaissie EJ, Hachem R, Karyotakis NC, et al. Comparative efficacies of amphotericin B, triazoles, and combination of both as experimental therapy for murine trichosporonosis. *Antimicrob Agents Chemother* **1994**; 38:2541–4.
10. Guého E, Improvisi L, de Hoog GS, Dupont B. *Trichosporon* on humans: a practical account. *Mycoses* **1994**; 37:3–10.
11. Espinel-Ingroff A. In vitro activity of the new triazole voriconazole (UK-109,496) against opportunistic filamentous and dimorphic fungi and common and emerging yeast pathogens. *J Clin Microbiol* **1998**; 36:198–202.