

RECOVERY OF LITTLE BROWN BATS (*MYOTIS LUCIFUGUS*) FROM NATURAL INFECTION WITH *GEOMYCES DESTRUCTANS*, WHITE-NOSE SYNDROME

Carol Uphoff Meteyer,^{1,8} Mick Valent,² Jackie Kashmer,³ Elizabeth L. Buckles,⁴ Jeffrey M. Lorch,⁵ David S. Blehert,¹ Amanda Lollar,⁶ Douglas Berndt,¹ Emily Wheeler,⁷ C. LeAnn White,¹ and Anne E. Ballmann¹

¹ National Wildlife Health Center, US Geological Survey, 6006 Schroeder Road, Madison, Wisconsin 53711, USA

² New Jersey Division of Fish and Wildlife, 1 Van Syckels Road, Clinton, New Jersey 08809, USA

³ Bat World New Jersey, P.O. Box 12, Pittstown, New Jersey 08867, USA

⁴ Cornell University, Department of Biomedical Sciences, Section of Anatomic Pathology, Veterinary Research Tower, T6 008, Upper Tower Rd, Ithaca, New York 14853, USA

⁵ Molecular and Environmental Toxicology Center, 1710 University Avenue, University of Wisconsin, Madison, Wisconsin 53726, USA

⁶ Bat World Sanctuary, 217 N. Oak Avenue, Mineral Wells, Texas 76067, USA

⁷ University of Illinois, Department of Animal Sciences & College of Veterinary Medicine, 462 Animal Sciences Laboratory MC630, Urbana, Illinois 61802-4734, USA

⁸ Corresponding author (email: cmeteyer@usgs.gov)

ABSTRACT: *Geomyces destructans* produces the white fungal growth on the muzzle and the tacky white discoloration on wings and ears that characterize white-nose syndrome (WNS) in cave-hibernating bats. To test the hypothesis that postemergent WNS-infected bats recover from infection with *G. destructans*, 30 little brown bats (*Myotis lucifugus*) were collected in May 2009 from a WNS-affected hibernation site in New Jersey. All bats were confirmed to be infected with *G. destructans* using a noninvasive fungal tape method to identify the conidia of *G. destructans* and polymerase chain reaction (PCR). The bats were then held in captivity and given supportive care for 70 days. Of the 26 bats that survived and were humanely killed after 70 days, 25 showed significant improvement in the external appearance of wing membranes, had no microscopic evidence of infection by *G. destructans*, and had wing tissue samples that were negative for *G. destructans* by PCR. A subset of the bats was treated topically at the beginning of the rehabilitation study with a dilute vinegar solution, but treatment with vinegar provided no added advantage to recovery. Provision of supportive care to homeothermic bats was sufficient for full recovery from WNS. One bat at day 70 still had both gross pathology and microscopic evidence of WNS in wing membranes and was PCR-positive for *G. destructans*. Dense aggregates of neutrophils surrounded the hyphae that remained in the wing membrane of this bat.

Key words: Bats, emerging fungal disease, *Geomyces destructans*, hibernation, *Myotis lucifugus*, white-nose syndrome.

INTRODUCTION

Estimates for mortality caused by white-nose syndrome (WNS) have exceeded one million bats since the disease was identified in New York in spring 2007; most of this mortality has been documented in little brown bats (*Myotis lucifugus*; Frick et al., 2010). Exuberant white hyphae around the muzzle and a white, tacky film on wings caused by infection with *Geomyces destructans* are characteristic field manifestations of WNS. Caves or mines with WNS-infected bats have seen rapid population declines as the disease recurs and intensifies through subsequent hiber-

nation cycles (Blehert et al., 2009). Population models have shown that these dramatic declines could lead to regional extinctions of *M. lucifugus*, one of the most common bat species in North America (Frick et al., 2010).

The majority of documented bat mortality associated with WNS has occurred during hibernation and may be due to physiologic imbalance caused by severe fungal infection, comparable to that in amphibians with chytridiomycosis (Cryan et al., 2010). Physiologic studies show that hibernation in mammals is associated with dramatic down-regulation of metabolism and immune response as body tempera-

tures drop to 2–10 C (Bouma et al., 2010). The body temperature of hibernating bats is well within the ideal range of approximately 1–15 C for the growth of *G. destructans* (Gargas et al., 2009). As bats arouse from hibernation, their metabolism and body temperatures increase to euthermic levels (34–39 C; Neuweiler, 2000), well above those permissive for growth of *G. destructans*. Neutrophilic inflammation in response to infection of hibernating bats by *G. destructans* is usually absent. Previous observations (Meteyer et al., 2009) and this study document a neutrophilic response to *G. destructans* after bats have emerged from hibernation. The lack of a visible cellular immune response to *G. destructans* during hibernation, with subsequent neutrophil recruitment and sequestration of *G. destructans* in homeothermic bats, suggests that bats have a cycle of suppression and reactivation of cellular immune response similar to mammalian models of immune regulation during and after hibernation (Bouma et al., 2010). This neutrophil response following emergence of bats from hibernation likely contributes to the recovery from natural infection with *G. destructans*. The topical application of apple cider vinegar was also evaluated as a possible treatment for WNS.

MATERIAL AND METHODS

Field collection

Thirty little brown bats with white foci on the muzzle or wings, consistent with WNS, were collected by hand in May from a confirmed WNS-affected hibernaculum in New Jersey. Bats were placed in individually numbered muslin bags. Fungal samples were obtained from the bats shortly after collection using Fungi-Tape (Scientific Device Laboratory, Inc., Des Plaines, Illinois, USA) pressed to the muzzle and wing. These strips of tape were placed directly onto 76 by 25 mm glass slides labeled with the individual bat identifier (Fig. 1A), and sent to the US Geological Service-National Wildlife Health Center (NWHC) for microscopic evaluation for the presence of conidia with morphology consistent with those of *G. destructans* (Gargas et al., 2009).

Rehabilitation, maintenance, and treatment

After capture, bats were transported by car to the Bat World New Jersey rehabilitation facility (New Jersey Division of Fish and Wildlife rehabilitation permit 291414) and randomly assigned to one of three groups. Bats were transferred to individual mesh cages, and each group of 10 bats was housed on a separate floor of the facility and maintained following bat rehabilitation protocols (Lollar, 2010). Upon arrival, bats were given 0.75 ml warm, lactated Ringers solution subcutaneously and allowed to stabilize for 10 days while adapting to a diet of 25–30 mealworms nightly. Bats were housed at temperatures ranging from 18.3 C to 23.9 C throughout the study. During the pretreatment stabilization period, four bats either died or were humanely euthanized by isoflurane overdose.

To assess whether a mildly acidic nontoxic solution might aid healing of wing membranes infected with *G. destructans*, a warmed food-grade apple cider vinegar solution diluted 1:1 with an equal volume of tap water was liberally applied using cotton swabs to the wing membrane and muzzle region of a subset of the bats. The wings were then allowed to air-dry while folded in their natural position. One group ($n=10$) received a single treatment with the dilute vinegar on night 11 postcapture; another group ($n=6$; 4 died prior to treatment) was treated on night 11 postcapture and nightly for three additional nights. The third group ($n=10$) was not treated. At the end of the 70-day study, bats were humanely killed by isoflurane overdose. Bats were then randomly divided into two groups and submitted to the NWHC and the Cornell College of Veterinary Medicine for gross and microscopic examination with particular attention to fungal colonization or changes consistent with WNS in the wing membrane. Postmortem and histologic analyses were conducted without prior knowledge of the treatment groups to which the individual bats belonged. Samples of wing membrane were collected at necropsy for polymerase chain reaction (PCR) analysis to detect a genetic signature of *G. destructans* (Lorch et al., 2010).

Detection of *G. destructans* and evaluation of lesions

Unstained slide-mounted tape impressions from newly collected bats (Fig. 1A) were evaluated without magnification, and areas with visible material were circled using a felt-tipped pen. Marked areas were then examined by light microscopy (40 \times objective)

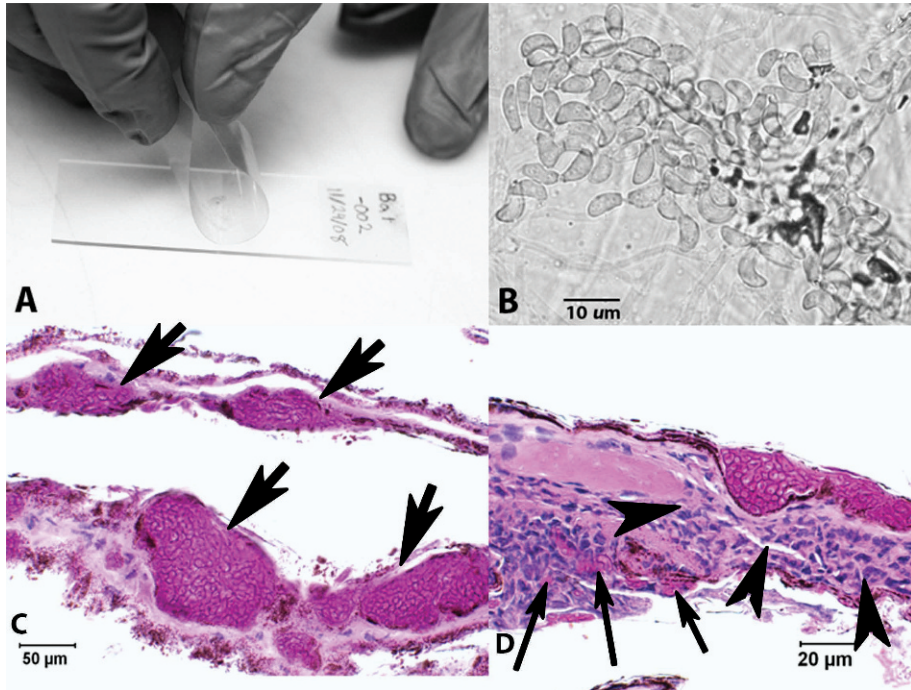


FIGURE 1. Studies of *Geomyces destructans*, fungal agent of white-nose syndrome affecting little brown bats (*Myotis lucifugus*) from New Jersey, USA, 2009. (A) Fungal tape-strip sampling method. After pressing the gently folded tape strip to the face and wings of a bat, the tape strip is mounted to labeled glass. After mounting, areas with contact debris are circled to facilitate examination using a microscope. (B) Microscopic appearance of unstained conidia from *G. destructans* as seen on a slide-mounted tape strip. (C) Periodic acid-Schiff (PAS)-stained section of wing from one of four little brown bats that died prior to treatment. Although dense packets of fungal hyphae form cup-like erosions in wing membrane (arrows), there is no evidence of inflammation in this region of infection. (D) PAS-stained section of wing membrane from same bat as in (C). Dense packets of hyphae erode epidermis. Degenerating neutrophils are present at the interface of these erosions and traverse the narrow connective tissue space of the wing membrane (arrowheads). At the opposite surface of wing membrane, degenerating neutrophils surround and sequester fungal hyphae in an inflammatory crust (arrows).

for conidia with morphology consistent with that of *G. destructans* (Fig. 1B). If no conidia were seen in marked areas, the entire tape strip was systematically reviewed. Changing the focus for different depths of field or removing the condenser from the path of transmitted light (if the microscope allows) can assist in detecting the refractile, unstained wall of the conidia.

Photographs of back-lit wings taken at 20, 27, and 70 days postcapture were assessed for severity of gross lesions. A published wing damage index (WDI; Reichard and Kunz, 2009) was used to score wing membranes without knowledge of individual bat identification, treatment group, observation period, PCR results, or histology findings. A WDI score of 0 was assigned when there was no obvious wing damage, and WDI scores of 1, 2,

and 3 represented mild, moderate, and severe damage, respectively. A proportional odds model (SAS v9.2, SAS Institute, Cary, North Carolina, USA) was used to determine whether there were statistically significant differences in WDI scores among treatment groups and observation periods. Tissues for histopathology evaluation were prepared similarly by both pathologists. With the exception of a 2 cm by 3 cm section of wing membrane that was submitted to the NWHC for *G. destructans* PCR testing, all remaining wing skin was removed for histopathology analysis using a method that maximized the surface area examined (Meteyer et al., 2009). Briefly, wing membrane was rolled onto small wooden dowels, fixed in 10% neutral-buffered formalin, trimmed in multiple cross-sections, and stained with periodic acid-Schiff (PAS). In

addition, the NWHC collected muzzle with nose and ear samples, which were trimmed perpendicular to the surface of skin. Skin sections were stained with PAS. White-nose syndrome was diagnosed microscopically by applying previously published diagnostic criteria for characteristic lesions including cup-like skin erosions filled with hyphae (Meteyer et al., 2009). Tissue sections from bats were shared to ensure conformity of interpretation between the pathologist at the NWHC and the Cornell College of Veterinary Medicine.

RESULTS

All 30 little brown bats had physical evidence of WNS when collected, and the distinctive conidia of *G. destructans* were identified on the slide-mounted tape strips prepared from all bats. All bats were male with an average right forearm length of 37.17 mm (range: 34.4–39.9 mm) and average body mass of 6.07 g (range: 5.3–6.7 g) at the time of collection. The four bats that died during the first week of rehabilitation had histopathologic changes in wing membranes that fulfilled the diagnostic criteria for WNS (Meteyer et al., 2009). These fungal infections were moderately extensive with dense packets of fungal hyphae eroding epidermis (Fig. 1C). There were multifocal areas of intense neutrophilic inflammation associated with fungal hyphae and fungal hyphae could be found in superficial inflammatory crusts (Fig. 1D), similar to previous microscopic observations in free-flying bats collected at the end of hibernation (Meteyer et al., 2009). Wing membranes from three of these four animals were PCR positive for *G. destructans*.

In 20 of the 26 bats, wing lesions appeared more severe on day 27 than day 20 (Figs. 2A, B). On day 20, individual bats were less likely (OR 0.03, 95% confidence interval [CI] 0.006–0.115) to have high wing scores than on day 27. No significant difference in WDI was detected among the three treatment groups ($\chi^2=0.1573$; $df=2$; $P=0.9244$). The interaction between treatment group and

observation period was not significant ($\chi^2=5.7617$; $df=4$; $P=0.2177$). Only the observation period had a significant effect on the WDI score ($\chi^2=22.73$; $df=2$; $P<0.0001$).

The most common lesions visible at day 20 were stellate areas of wing membrane that resembled dense tissue when back-lit (Figs. 2A, 3A, and 3B). These changes may represent areas of wing membrane contraction, cellular infiltrate, or local adherence of wing membrane surfaces. Excessive manipulation of the wings to determine the cause of this change was not performed to prevent stress or handling-induced damage to wing membrane. Photographs at day 27 often showed areas of pallor (Figs. 2B and 3C) interpreted as membrane thinning or tissue loss in regions of the wing that had previously shown stellate densities.

Qualitative and semiquantitative evaluation of back-lit wings showed 22 of 25 bats (85%) had increased lesion scores on day 27 compared to day 20 (Table 1). The WDI decreased by day 70 compared to day 27 in most bats (OR 0.11; 95% CI 0.03–0.41). Photographs at the end of the 70-day study showed a decrease in wing lesion scores with noted improvement in wing membranes of 24 of 25 bats (96%). No gross lesions were observed in the wings of 12 bats on day 70 (Figs. 2C and 4), and only mild multifocal pinpoint areas of pallor were observed in 13 bats. The untreated group had an average WDI of 1.6 on day 27 and 0.5 on day 70 (Table 1), indicating improvement. The average WDI on days 27 and 70 for bats with one treatment were 1 and 0.4 respectively, and 1 and 0.8 for bats treated four times. Photographs taken on day 70 scored higher than day 20 (OR 4.3; 95% CI 1.2–14.8). The average WDI on day 20 was 0.2 and on day 70 was 0.5.

The 25 bats with minor or no gross lesions at the end of the 70-day period of supportive care also had no significant gross or microscopic pathology or evidence of *G. destructans* in their wing

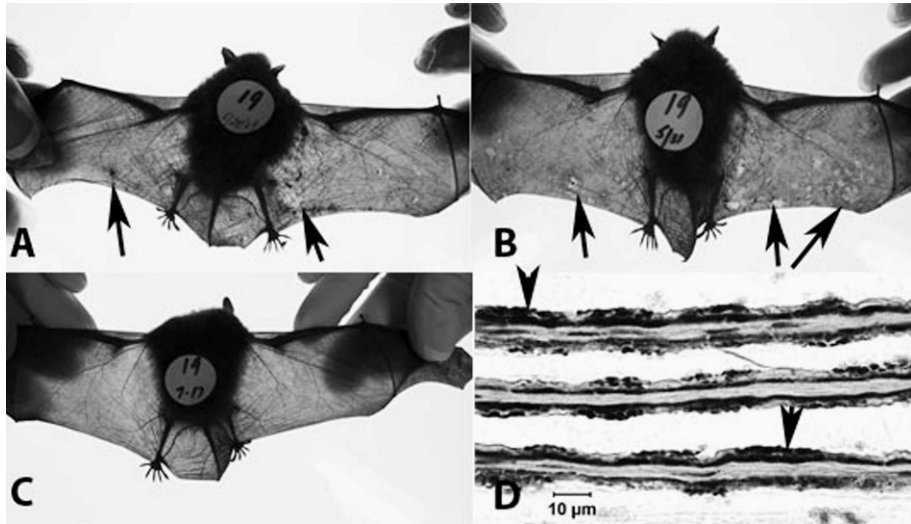


FIGURE 2. Effects of *Geomyces destructans*, fungal agent of white-nose syndrome (WNS) on little brown bats (*Myotis lucifugus*) from New Jersey, USA, during a recovery experiment, 2009. (A–C) Sequential back-lit photographs taken of the same little brown bat at 20, 27, and 70 days postcapture. This bat was given supportive care but was not treated with vinegar. These sequential changes are representative of 25 bats that showed recovery from WNS at the end of the 70-day study. (A) Irregular pattern of increased stellate density (arrows), photographed on day 20. (B) Day 27, lesions are more numerous and appear more severe. Translucent areas of wing membrane suggest thinning or loss of epidermis (arrows). Areas of increased density and contraction are still present but are less obvious. (C) At the end of the study, following 70 days of supportive care without treatment, wing membranes show recovery without evidence of lesions. (D) Periodic acid-Schiff–stained microscopic section of wing membrane collected from this bat after humane termination on Day 70. The anatomy of wing membrane is normal with intact epidermis (arrowheads) and no inflammation or scarring.

membranes (Fig. 2C, D). Wing skin samples were also PCR-negative for *G. destructans* in all 25 bats. Unlike these 25 bats, one additional bat (treated with vinegar for four consecutive nights) showed little change in the condition of wing membrane scores during the first 4 wk of rehabilitation (Fig. 3A, B) but had higher WDI scores with numerous coalescing areas of pallor on day 70 (Fig. 3C). This also was the only surviving bat that did not gain mass during the study, losing 1.29 g over the 70-day period. Although much of the wing membrane was histologically unremarkable, this bat had focal areas of intense neutrophilic inflammation with superficial inflammatory crusts containing fungal hyphae; these crusts were separating from intact epidermis (Fig. 3D), similar to those seen in the four bats that died prior to treatment. The

wing skin sampled from this bat was PCR-positive for *G. destructans*.

At the end of the study, no inflammation was evident in the histologic sections of wing membrane from nine of the untreated bats, two of the singly treated bats, and three of the bats treated four times (Table 1). The remaining 12 bats had random mild to focally moderate mononuclear cell inflammation of wing membrane. Three bats that were treated four times with vinegar had lymphocytic inflammation in the perifollicular dermis of the muzzle; no cause was identified for this inflammation and no fungal hyphae were seen. The untreated bats ($n=10$) had an average mass increase of 4.09 g (range: 1.68–7.33 g); the group treated once with vinegar ($n=10$) gained 4.21 g (range: 1.87–6.26 g); and the group treated four times with vinegar ($n=6$), which included the

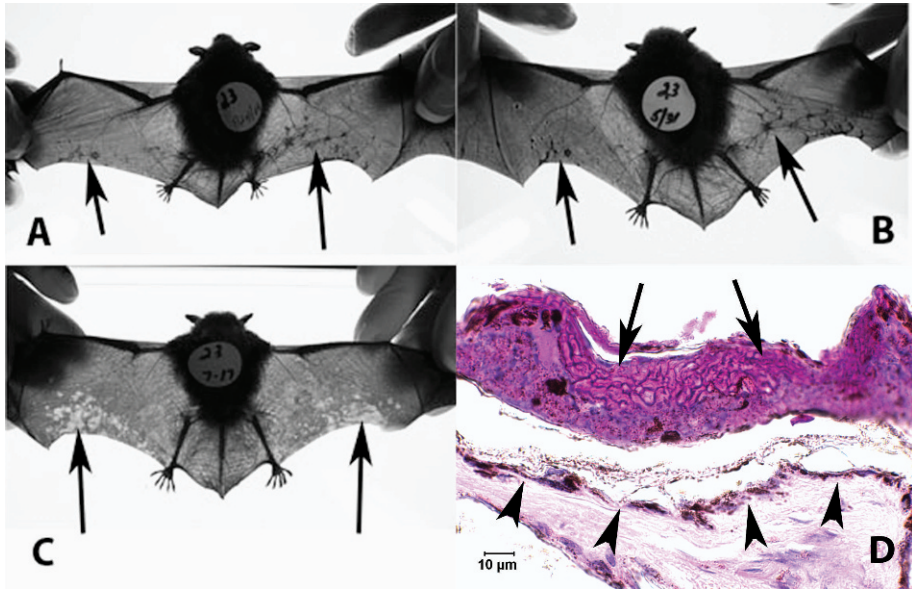


FIGURE 3. Treatment of a little brown bat (*Myotis lucifugus*) from New Jersey, USA, infected with *Geomyces destructans*, fungal agent of white-nose syndrome (WNS). (A–C) Sequential back-lit photographs of the same little brown bat taken at 20, 27, and 70 days postcapture. The wing membrane was treated four times with dilute vinegar during 1 wk. This is the only bat of 26 (treated or untreated) that did not completely recover from WNS during 70 days of supportive care. (A) Photograph taken on day 20 showing an irregular pattern of stellate densities (arrows). (B) Photograph taken on day 27 shows little change from day 20. (C) Photograph taken day 70 after 10 wk of supportive care. Numerous translucent areas of wing membrane suggest thinning or loss of epidermis (arrows). Areas of increased density and contraction are no longer present. (D) Periodic acid-Schiff-stained microscopic section of wing membrane collected after the photograph was taken in Fig. 3C. There is intact epithelium (arrowhead) and the superficial serocellular crust containing fungal hyphae (arrow) is separating from the epithelium.

bat that remained infected with *G. destructans*, gained 2.84 g (range: -2.19 g to 5.06 g).

DISCUSSION

This is the first report of bats recovering from infection with *G. destructans* and WNS. At the end of the 70-day observation period, photographic assessment and microscopic examination of wings in 25 of 26 surviving bats showed no significant wing lesions and no gross or microscopic evidence of fungal infection. In addition, PCR tests for *G. destructans* were negative, indicating recovery. Recovery occurred in both vinegar-treated and untreated little brown bats. Increasing body temperature and supportive care were adequate for recovery from WNS, and

topical application of vinegar did not provide an advantage to recovery beyond that afforded by supportive care. Recovery of naturally infected, postemergent bats and the presence of intense neutrophilic response in five bats that were necropsied prior to recovery provide evidence that, once bats become homeothermic, neutrophils respond to the fungal hyphae of *G. destructans*.

The normal suppression of the immune response in mammalian hibernators (Bouma et al., 2010) likely occurs in bats during hibernation. This is consistent with our findings that *G. destructans* can invade the living tissue of hibernating bats without eliciting a cellular inflammatory response. This lack of inflammation seems to confer a biological advantage to *G. destructans*. The euthermic body temper-

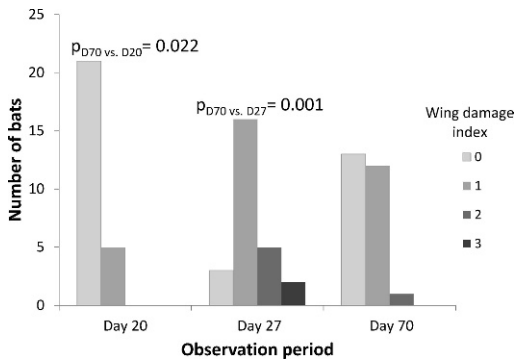


FIGURE 4. Distribution of wing damage index scores in photographs taken at 20, 27, and 70 days postcapture for 26 little brown bats (*Myotis lucifugus*) naturally infected with *Geomyces destructans*, fungal agent of white-nose syndrome. Wing damage scores (increasing in severity from 0 through 3) differed significantly (proportional odds model SAS v9.2) at all time points with the highest frequency of moderate to severe wing damage occurring at day 27. On day 70 wing damage scores were zero for 50% of the bats indicating resolution of lesions, and 46% of the bats had a mild wing damage score of 1.

ature of bats, well above temperatures permissive to the growth of *G. destructans*, accompanied by the cellular immune response described here, seem adequate to overcome infection by the fungus in posthibernal bats.

Photographs of wing membrane from the single bat that did not recover from WNS indicated that the condition of its wings worsened throughout the course of the study (Fig. 3). When the sections of wing from this bat were examined microscopically, fungal hyphae and lesions that fulfilled the criteria for WNS were still present and associated with a neutrophilic inflammatory response (Fig. 3D). The wing lesions seen in photographs of this bat on day 20 were indistinct from those identified in the other 25 bats on that day. However, comparison of photographs of this bat with those of the other 25 bats on days 27 and 70 showed that the recovery of this bat was delayed.

Recovery of bats naturally infected with *G. destructans* when provided supportive care (e.g., warmth, food, and water) following emergence from hibernation

suggests that free-ranging bats may also recover from WNS if they are able to survive the postemergence healing process. A 2008 study of little brown bats at maternity roosts in the range of WNS (Reichard and Kunz, 2009) documented wing lesions in these bats and developed the wing damage index applied in our study. The 2008 study reported that severe wing lesions (WDI 3) were most commonly seen during May and the “relative abundance of bats with obvious wing damage peaked in June” (Reichard and Kunz, 2009, p. 460). Bats with WDI >2 were not seen after the second week in July. The sequence of observations in the 2008 study parallel the results of this study with a shift from severe wing lesions observed in the late spring, to normal wings in early summer. The wing lesions illustrated in Reichard and Kunz (2009, fig. 1) were similar to the changes we saw in photographs taken on day 27 (Fig. 2C) and those taken of the single bat with progressive lesions on day 70 (Fig. 3C). Reichard and Kunz did not address the possibility that lesions were not seen after the second week in July due to recovery and felt that the wing damage was permanent and fatal.

Although 25 of the 26 bats were PCR-negative for DNA from *G. destructans* at the end of this 70-day study, it is possible that fungal hyphae or conidia may remain associated with bat skin or fur after bats recover from fungal infection. If these fungal elements remain viable, but presumably dormant throughout the active, homeothermic, summer season, it is possible that when bats re-enter hibernation, the cool temperatures, high humidity, and drop in the bat’s body temperature could promote renewed growth of the fungus and subsequent recrudescence of WNS without reinfection.

Posthibernal bats have been found dead or unable to fly near hibernation sites or roost sites in WNS-affected areas (Reichard and Kunz, 2009). A subset of these (Meteyer et al., 2009) had histopathology

TABLE 1. Summary of mass change, wing scores, *Geomyces destructans* (*Gd*) polymerase chain reaction (PCR), and histopathology analyses for rehabilitated little brown bats (*Myotis lucifugus*) by treatment group.

Vinegar treatment group ^a	Mass change ^b	Wing score (day 20) ^c	Wing score (day 27)	Wing score (day 70)	<i>Gd</i> PCR (day 70)	Histopathology (day 70) ^d
None	4.15	0	1	0	—	W, Mz, E: all unremarkable
None	1.68	0	1	1	—	W, Mz, E: all unremarkable
None	4.63	0	1	0	—	W, Mz, E: all unremarkable
None	5.45	0	1	1	—	W, Mz, E: all unremarkable; one mite
None	4.96	0	1	0	—	W, Mz, E: all unremarkable
None	4.02	0	3	1	—	W: unremarkable
None	1.72	0	2	1	—	W: unremarkable
None	5.04	0	2	1	—	W: unremarkable
None	7.33	0	1	0	—	W: unremarkable
None	1.95	1	3	0	—	W: multiple foci of neutrophils; no cause
1×	5.72	1	1	0	—	W: rare lymphocytes; Mz, E: unremarkable
1×	1.87	0	1	0	—	W: rare lymphocytes; Mz, E: unremarkable
1×	1.79	0	1	0	—	W: rare lymphocytes; Mz, E: unremarkable
1×	6.26	0	0	1	—	W,E: unremarkable; Mz: small, deep foci of lymphocytes; no cause
1×	4.49	0	1	0	—	W: mild to focally moderate mononuclear cell inflammation; Mz: mild lymphocytic perifolliculitis; E: unremarkable; no cause
1×	5.24	1	1	1	—	W: unremarkable; one mite
1×	5.10	0	1	0	—	W: single deep focus of neutrophils with rare macrophages and lymphocytes; no cause
1×	4.38	0	2	1	—	W: focus of transmembrane keratin; no cause
1×	4.04	1	1	0	—	W: a few dilated adnexa
1×	2.82	0	1	1	—	W: unremarkable
4×	3.59	0	0	1	—	W, Mz, E: all unremarkable
4×	4.15	0	1	1	—	W, Mz, E: all unremarkable
4×	5.06	1	2	0	—	W, Mz, E: all unremarkable
4×	3.11	0	1	0	—	W: single focus of neutrophils with mild hyperkeratosis; no cause
4×	-1.29	0	0	2	+	W: white-nose syndrome positive with neutrophils and lymphocytes
4×	2.42	0	2	1	—	W: a few neutrophils, neutrophil crusts, rare lymphocytes; no cause

^a 1× = single treatment; 4× = four treatments.

^b Determined by subtracting mass at end of the experiment (day 70) from mass at intake.

^c Wing damage index score (Reichard and Kunz, 2009): 0 = no damage; 1 = mild damage; 2 = moderate damage; 3 = severe damage.

^d W = wing; Mz = muzzle; E = ear.

performed that confirmed WNS as the cause of the severe wing damage with severe neutrophilic inflammation associated with the fungal hyphae (Meteyer et al., 2009). Therefore, recovery of wild bats from WNS following emergence from hibernation is not guaranteed. Recovery from WNS not only depends on healing processes that repair damage to wing membranes caused by fungal infection, but infected bats must simultaneously maintain hydration and a positive energy balance and avoid predators despite potential flight impairment due to damaged wings. The severe wing pathology of WNS is temporally and additively associated with neutrophil response to *G. destructans*. This inflammation-associated pathology likely also contributes to compromised flight ability and survival during the vulnerable period following emergence from months of hibernation. To understand this potential complication in bats recovering from WNS, it will be important to understand normal immunology of hibernating bats and the role of the neutrophil response to *G. destructans* in posthibernal bats.

ACKNOWLEDGMENTS

We thank Christina Kocer, Connecticut Department of Environmental Protection, Wildlife, and Susi von Oettingen and Annette Scherer from the US Fish and Wildlife Service for their input with the study design; Nathan Ramsay for photo archiving; and Paul Cryan and Krysten Schuler for manuscript review. Partial funding was provided by the US Fish and Wildlife Service 2008 State Wildlife Grant to Pennsylvania. This study was approved by the New Jersey Division of Fish and Wildlife, Endangered and Nongame Species Program, and the procedures for sampling and euthanasia of bats were approved by Institutional Animal Care and Use Committees of the US Geological Survey following the American Veterinary Medical Association's Guidelines on Euthanasia and the Guidelines of the American Society of Mammalogists for the Use of Wild Mammals in Research and by the US Geological Survey National Wildlife Health Center Animal Care and Use docu-

ment EP081124-A1. Use of trade, product, or firm names is for descriptive purposes only and does not imply endorsement by the US Government.

LITERATURE CITED

- BLEHERT, D. S., A. C. HICKS, M. J. BEHR, C. U. METEYER, B. M. BERLOWSKI-ZIER, E. L. BUCKLES, J. T. H. COLEMAN, S. R. DARLING, A. GARGAS, R. NIVER, J. C. OKONIEWSKI, R. J. RUDD, AND W. B. STONE. 2009. Bat white-nose syndrome: an emerging fungal pathogen? *Science* 232: 227.
- BOUMA, H. R., H. V. CAREY, AND F. G. M. KROESE. 2010. Hibernation: The immune system at rest? *Journal of Leukocyte Biology* 88: 1–6.
- CRYAN, P. M., C. U. METEYER, J. G. BOYLES, AND D. S. BLEHERT. 2010. Wing pathology of white-nose syndrome in bats suggests life-threatening disruption of physiology. *BioMed Central Biology* 8: 135 (11 November 2010). <http://www.biomedcentral.com/1741-7007/8/135>.
- FRICK, W. F., J. F. POLLOCK, A. C. HICKS, K. E. LANGWIG, D. S. REYNOLDS, G. R. TURNER, C. M. BUTCHKOSKI, AND T. H. KUNZ. 2010. An emerging disease causes regional population collapse of a common North American bat species. *Science* 329: 679–682.
- GARGAS, A., M. T. TREST, M. CHRISTENSEN, T. J. VOLK, AND D. S. BLEHERT. 2009. *Geomyces destructans* sp. nov. associated with bat white-nose syndrome. *Mycotaxon* 108: 147–154.
- LOLLAR, A. 2010. Standards and medical management for captive insectivorous bats [modified 28 February 2011]. Bat World Publication, Mineral Wells, Texas, 222 pp.
- LORCH, J. M., A. GARGAS, C. U. METEYER, B. M. BERLOWSKI-ZIER, D. E. GREEN, V. SHEARN-BOCHSLER, N. J. THOMAS, AND D. S. BLEHERT. 2010. Rapid polymerase chain reaction diagnosis of white-nose syndrome in bats. *Journal of Veterinary Diagnostic Investigation* 22: 224–230.
- METEYER, C. U., E. L. BUCKLES, D. S. BLEHERT, A. C. HICKS, D. E. GREEN, V. SHEARN-BOCHSLER, N. J. THOMAS, A. GARGAS, AND M. J. BEHR. 2009. Histopathologic criteria to confirm white-nose syndrome in bats. *Journal of Veterinary Diagnostic Investigation* 21: 411–414.
- NEUWEILER, G. 2000. The biology of bats. E. Covey (translator). Oxford University Press, Inc., New York, New York, 310 pp.
- REICHARD, J. D., AND T. H. KUNZ. 2009. White-nose syndrome inflicts lasting injuries to the wings of little brown myotis (*Myotis lucifugus*). *Acta Chiropterologica* 11: 457–464.

Submitted for publication 15 November 2010.

Accepted 11 March 2011.