

# UC Davis

## UC Davis Previously Published Works

### Title

Patella Baja in Total Knee Arthroplasty.

### Permalink

<https://escholarship.org/uc/item/4nc0x52p>

### Journal

Journal of the American Academy of Orthopaedic Surgeons, 28(8)

### ISSN

1067-151X

### Authors

Lum, Zachary C  
Saiz, Augustine M  
Pereira, Gavin C  
et al.

### Publication Date

2020-04-15

### DOI

10.5435/jaaos-d-19-00422

Peer reviewed

# Patella Baja in Total Knee Arthroplasty

Zachary C. Lum, DO 

Augustine M. Saiz, MD 

Gavin C. Pereira, MBBS, FRCS  
(Eng) (T&O)

John P. Meehan, MD

## Abstract

Patella baja in total knee arthroplasty can result in impingement, pain, and decreased range of motion. Etiology can range from previous knee surgeries such as anterior cruciate ligament reconstruction, retrograde femoral nail, infrapatellar fat pad resection, and previous total knee arthroplasty. Diagnosis can be confirmed by one of a number of measurements of patellar height including Insall-Salvati and Blackburne-Peel ratios. It is important to differentiate between true patella baja and pseudopatella baja by patellar height ratio. Treatment includes correct identification of the underlying etiology and appropriate management. Surgical management strategies include tibial tubercle osteotomy, distal femoral augment and revision, proximalization of the patellar component, modification of the anterior tibial component, and/or Z-plasty of the patellar tendon. We review the outcomes for each of these procedures.

Patella is derived from the Greek word “patanē” which means “a plate” and subsequently Latin for “patina” or “shallow dish.” Baja is Spanish for “low.” Previously, patella baja was called patella infera, where infera was Latin for “below.”

Classically, patella baja was defined as the space between the inferior pole of the patella and the upper tibia being less than 1 to 2 cm.<sup>1</sup> Broader terms suggest patella baja to be an abnormally low-lying patella which is associated with restricted range of motion, crepitations, and retropatellar pain.<sup>2</sup> A more comprehensive definition characterizes patella baja through position in the femoral trochlea with a decreased distance between the inferior pole of the patella and the articular surface of the tibia with or without permanent shortening of the patellar tendon.<sup>3</sup>

The primary biomechanical function of the patella is to improve quadriceps efficiency by increasing the lever arm of the extensor mechanism.

The extensor mechanism consists of the quadriceps muscle group and tendon, the patella, the patellar ligament, the tibial tubercle, and the patella retinaculum. The force necessary for knee extension is directly dependent on the perpendicular distance between the patellar tendon and the knee flexion axis.<sup>4</sup> In addition, from 45° of flexion to full extension, the patella is the only component of the extensor mechanism in contact with the femur causing the extensor mechanism to be displaced away from the axis of the knee, increasing the effective moment arm of the quadriceps tendon, creating a mechanical advantage analogous to that of a pulley.<sup>4</sup>

In patella baja, the patella is always in contact with the trochlea in extension, in contrast to a normal patella. This can cause impingement leading to anterior knee pain and joint stiffness. In addition, the patella baja results in a decreased lever arm and subsequent extensor lag resulting in a reduction in range of motion.<sup>4</sup>

From the Adult Reconstruction Division, Department of Orthopaedic Surgery, University of California: Davis Medical Center, Sacramento, CA.

None of the following authors or any immediate family member has received anything of value from or has stock or stock options held in a commercial company or institution related directly or indirectly to the subject of this article: Dr. Lum, Dr. Saiz, Dr. Pereira, and Dr. Meehan.

*J Am Acad Orthop Surg* 2020;28:316-323

DOI: 10.5435/JAAOS-D-19-00422

Copyright 2020 by the American Academy of Orthopaedic Surgeons.

Patella baja was first described by Blazina et al<sup>5</sup> in 1975 at the American Academy of Orthopaedic Surgeon Proceedings. They described 10 cases of patella baja arising in a series of 40 cases of tibial tubercle transfer for patellar instability. The common features they described were: (1) immediate disability after surgery, (2) retropatellar pain and crepitus, (3) limitation of motion, and (4) distal displacement of the patella confirmed by physical examination and roentgenographic studies. Lancourt additionally described patella baja (“infera”) in a landmark article in 1975.<sup>6</sup> They used the Insall-Salvati measurement method to characterize patellar dislocators, patellar chondromalacia, tibial tubercle apophysitis, and controls. They concluded patella baja may be associated with tubercle apophysitis. More importantly, this was the first peer-reviewed journal publication to describe naturally occurring patella baja. Cameron and Bok-Jung appear to be the first to describe patella baja in total knee arthroplasty (TKA) in 1988.<sup>7</sup> They described two cases of preoperative patella baja from previous fractures undergoing TKA treated successfully with tibial tubercle osteotomy and proximalization allowing for appropriate patellar tracking. These cases revealed severe preoperative baja with lack of patellar contact with the femur during range of motion. Intraoperatively, during tibial tubercle proximalization, the authors ensured patellar contact with the femur during range of motion to gauge appropriate patellar height.

Since then, modern literature has revealed improved techniques for diagnosis and treatment in patella baja in TKA. The purpose of this article is to review the etiology, diagnosis, differential, surgical treatment, and outcomes of TKA patients with symptomatic patella baja.

## Etiology

Patella baja can be a resultant of many causes. This first distinction is between congenital and acquired. Congenital patella baja has three distinguishing characteristics: (1) distal positioning of the patella in the femoral trochlea, (2) shortening of the length of the patellar tendon, and (3) decreased distance between the distal pole of the patella and the articular surface of the proximal tibia.<sup>8</sup> These characteristics must not be attributable to trauma or surgery and present since childhood. Acquired causes of patella baja include patellar fracture, anterior cruciate ligament (ACL) reconstruction, high tibial osteotomy (HTO), knee arthroscopy, retrograde femoral nailing, unicompartmental knee arthroplasty (UKA), and the focus of this article, TKA.<sup>8-11</sup>

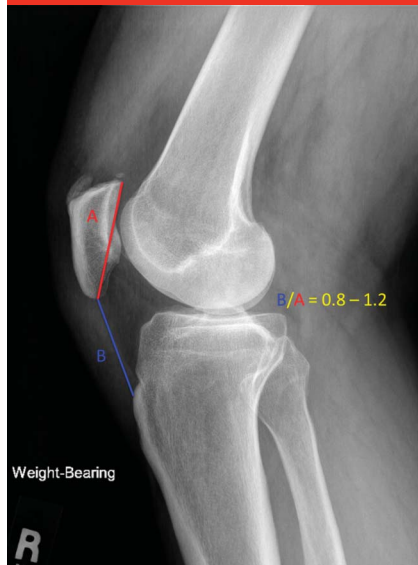
The above acquired etiologies can be differentiated into two different forms: a chronic and an acute patella infera syndrome.<sup>10</sup> In chronic conditions, permanent shortening of the patellar ligament is due to inflammatory events associated with other factors such as quadriceps weakness or inhibition or immobilization after femur fractures, HTO, UKA, or ACL reconstruction. There is a progressive distal descent of the patella, and the condition through different stages may lead to a permanent shortening of the patellar ligament. In acute patella baja, the patella may lower immediately after an injury such as after patellar fracture. After fracture, the patellar height remains stable or worsens during subsequent treatment.<sup>10</sup>

In the setting of trauma or surgery, patella baja may be due to multiple etiologies. Case reports from patients with previous surgeries such as retrograde femoral nailing suggest scarring around the patellar tendon, the retropatellar fat pad, and contracture of the patellar tendon.<sup>12,13</sup> Opening HTO,

to treat unicompartmental arthritic disease, classically results in an elevated tibial joint line and subsequent patella baja, although closing wedge osteotomy can result in patella baja as well.<sup>14</sup>

Patellar tendon shortening after TKA is a widely recognized complication with an incidence reported up to 34% with the greatest amount of shortening occurring in those patients who had a lateral release.<sup>15</sup> Recent evidence supports this finding as Davies et al<sup>16</sup> determined an incidence of 38% for patella baja after TKA in which the patella tendon shortened by at least 10% compared with preoperative measurements. This shortening is believed to be due to ischemic or traumatic injury sustained during surgery leading to a transient tendon shortening after peripatellar and fat pad contractures and quadriceps weakness.<sup>17</sup> Recent literature suggests that retention of the infrapatellar fat pad may decrease patella baja due to decreased ischemic injury.<sup>18</sup> This can be followed by joint stiffness due to associated arthrofibrosis, permanent shortening of the tendon, and eventual onset of patellofemoral arthrosis. Other causes are believed to be the formation of new bone or tethering of the tendon by intra-articular fibrous bands.<sup>19</sup> Furthermore, scarring of the patella to the retinaculum may also cause patella baja.<sup>8</sup> To the best of our knowledge, patella baja has not been reported in patellar resurfacing.

A cause of patella baja unique to TKA can be a result of alterations in the level of the joint line or relative position of the patella in the trochlea: distalizing the femoral joint line or raising the tibial joint line. Alterations of the patella-tibial distance can occur as a result of an overly aggressive distal femoral resection, excessive soft-tissue or ligamentous release, or lower placement of the patellar polyethylene component.<sup>20</sup>

**Figure 1**

Normal Insall-Salvati ratio and how to measure.

Distal positioning of the polyethylene component on the patella can decrease the distance between the patella and articular surface of the tibia.<sup>21</sup> In addition, TKA can have narrowing of the distance between the distal pole of the patella and the articular surface of the tibia without shortening of the patellar tendon. These causations were termed pseudopatella baja by Grelsamer.<sup>22</sup> This pseudopatella baja was noted to occur in 26 primary TKAs.<sup>23</sup>

Recent controversy exists regarding whether manipulation of the patella during TKA may affect the postoperative patellar height. Especially among proponents of minimally invasive surgery TKA, where patellar eversion is avoided, there has been suggestion that eversion of the patella causes shortening of the patellar tendon and poorer outcomes secondary to development of patella baja.<sup>3</sup> Flören et al, described a lower incidence of postoperative patella baja from 37% with standard approach to 12% with a less-invasive approach in which the patella is only

displaced but not everted. However, Sharma et al,<sup>24</sup> reported an incidence of less than 1% of patella baja after patellar eversion in TKA.

Some authors believe that the surgical technique of TKA may inherently result in patella baja. Specifically, fat pad excision and lateral release can lead to ischemia of the patellar tendon.<sup>25</sup> In addition, manipulation of the tendon and postoperative changes can lead to scarring and tissue contraction. UKA may maintain patellar height. A study by Weale et al<sup>15</sup> demonstrated that patella baja occurred in 34% of TKAs compared with 5% of UKA at five years postop. They concluded it was due to limited dissection needed for UKA. A study by Davies et al<sup>16</sup> also demonstrated that UKA, whether medial or lateral, did not cause patellar shortening whereas TKA did. Anagnostakos et al<sup>26</sup> reported on postoperative patella baja in a group of 41 UKAs up to 1 year postoperatively. Although they did not have any strong conclusion for etiology, they did find that patella baja was markedly more common in men, age >65 years, and left-sided knees.

Of interest, UKA sometimes resulted in perceived patella tendon lengthening. This may be due to previous tendon shortening from arthritic pain and degenerative processes that after surgery are corrected as function improves.<sup>16</sup> However, this does not represent a comprehensive explanation as both TKA and UKA report improved outcomes and function. Overall, more prospective research directly investigating patellar length after knee arthroplasty is needed.

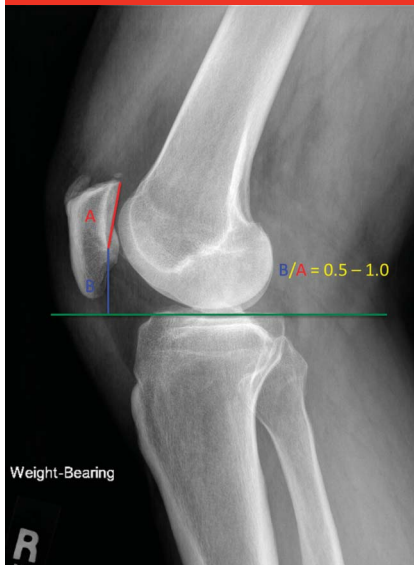
## Diagnosis

The definition of patella baja by Blazina et al<sup>5</sup> included the four tenets of a radiographic low-lying patella with symptomatic pain, poor func-

tion, and decreased range of motion. There has been development of several different methods to measure patellar height and patella-tibial distance to diagnose patella baja.

- (1) The first method was described in 1938 using Blumensaat<sup>27</sup>'s line. Patellar height is measured from a sagittal radiograph with the knee flexed 30°. Blumensaat's line should intersect the inferior pole of the patella in the normal knee.
- (2) The Insall-Salvati ratio was described in 1971.<sup>28</sup> The length of the patella tendon is used as the numerator and the length of the longest portion of the patella as the denominator to form a ratio. The ratio should be 1.0; however, it can range from 0.8 to 1.2 in normal knees. A recent study demonstrated that 10% of TKA patients develop patella baja defined as an Insall-Salvati ratio less than 0.8<sup>29</sup> (Figure 1).
- (3) The Insall-Salvati ratio was modified in 1992 by Grelsamer and Meadows.<sup>30</sup> This modified method used length of the patellar tendon as the numerator but changed the denominator to the length of the articular surface of the patella. The ratio averaged 1.5 in normal knees with almost all normal knees having a ratio less than 2.
- (4) Blackburne and Peel<sup>31</sup> described their method in 1977. Lateral radiographs are obtained at 30° of flexion. A line is projected forward from the tibial plateau and measurement taken from the distal end of the articular surface of the patella to the intersection of the tibial plateau line. A second measurement then is made across the articular surface of the patella. A ratio of the first and second measurement is made with normal knees falling in between 0.5 to 1. A recent study used the

Figure 2

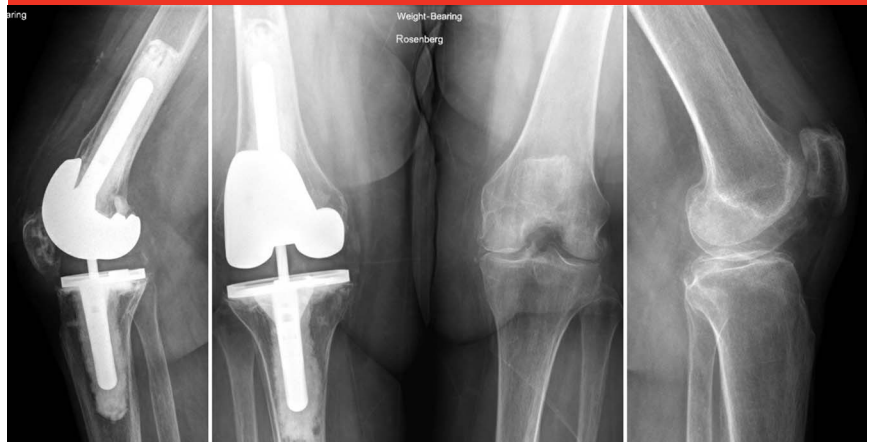

Normal Blackburne-Peel ratio and how to measure.

Blackburne-Peel ratio and determined that this ratio was predictive of worse outcomes if decreased<sup>32</sup> (Figure 2).

- (5) The Caton-Deschamps method described by Canton in 1982 measures the distance from the distal portion of the articular surface of the patella to the anterior-superior angle of the tibial plateau on lateral radiographs with the knee flexed 30°. <sup>33</sup> The length of the articular surface of the patella is measured. The ratio of these two measurements is taken with a normal knee falling between 0.6 to 1.3.
- (6) Recently, the patella-plateau angle has been developed to measure patellar height on a lateral radiograph. <sup>34</sup> It has been touted as a simple angular measurement with a higher intraobserver correlation. An angle from the tibial plateau from anterior to posterior toward the most inferior articular surface of the patella is drawn. Normal is between 21° and 29°.

Figure 3



True patella baja in a total knee arthroplasty. Note the preoperative (right) normal patellar height ratios and subsequent postoperative (left) abnormal ratios of both Insall-Salvati and Blackburne-Peel.

A recent study compared the Insall-Salvati, Blackburne-Peel, and Caton-Deschamps methods for measuring patellar height after TKA. <sup>35</sup> The methods were determined to be reproducible, and preoperative and postoperative patellar heights were not statistically different regardless of method used.

### Pseudopatella Baja

Once patella baja is diagnosed on a lateral postoperative TKA radiograph, the next step is to differentiate true from pseudopatella baja. As previously discussed, true patella baja is present when the length of the patellar tendon becomes shorter than normal (Figure 3), whereas elevation of the joint line without change in length of the patellar tendon is termed pseudopatella baja. Differentiation between the two may be done by radiographic means. In true patella baja, both modified Insall-Salvati ratio and Blackburne-Peel ratio will be abnormally low. In pseudopatella baja, Insall-Salvati ratio will be normal; however, Blackburne-Peel ratio will be low (Figure 4).

Elevation of the joint line (and therefore pseudopatella baja) can

be inadvertently achieved intraoperatively by:

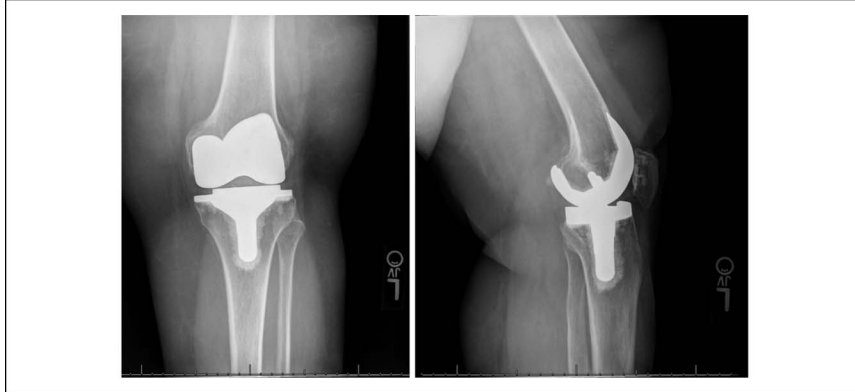- (1) Elevating the femoral joint line (excessive distal femoral cut, and consequently posterior femoral cut to achieve equal balance);
- (2) Elevating the tibial joint line (under-resecting the tibial cut and replacing it with the tibial baseplate and insert that is thicker than the resected bone);
- (3) Excessive soft-tissue release necessitating elevation of the tibiofemoral joint line to provide stability. <sup>21</sup>

Of a cohort of 60 patients, Kazemi et al <sup>21</sup> determined that the joint line was elevated (pseudopatella baja) in 25% after TKA resulting worse in outcomes affecting range of motion (ROM) and pain scores. Thornton-Bott et al <sup>36</sup> found that the incidence of pseudopatella baja increases with the extent of soft-tissue release, increase in insert thickness, and that TKA undergoing extensive soft-tissue release increases the risk of pseudopatella baja by 100%.

Pseudopatella baja occurs more commonly in revision TKA. The revision algorithm may result in an elevated tibial joint line and balance the flexion and extension gap without



Figure 4



Pseudopatella baja in a total knee arthroplasty. Note the normal Insall-Salvati ratio and abnormal Blackburn-Peel ratio, indicating this patient had an elevated joint line.

sufficient femoral augments. Surgeons should pay attention to the joint line preoperatively using fibular head (within 1 to 1.5 cm), intraoperatively using relative measurements to the medial and lateral epicondyles (25 mm from medial epicondyle and 30 mm from lateral epicondyle), as well as using intraoperative radiographs to help avoid this complication.<sup>37</sup> Pereira et al<sup>38</sup> proposed different ratios that could be used to calculate the knee joint line from bony landmarks. They found that the joint line is equidistant between the lateral femoral epicondyle and the proximal tibiofibular joint. In addition, the femoral joint line is one-third the interepicondylar diameter from the lateral epicondyle. Also, the tibial joint line measured from the corner of the tibial tubercle is half the tibial sagittal diameter. Using these data, they proposed a 3-step algorithm to avoid the problem of patella baja in revision and complex TKA: (1) intraoperative awareness of patellar tracking, (2) a stepwise algorithmic approach for flexion contracture correction, and (3) placing the joint line of the reconstruction as closely as possible to the natural joint line, and consistent early and effective

rehabilitation with appropriate analgesia is of paramount importance to prevent pseudopatella baja.

Pseudopatella baja due to joint line elevation can be addressed in multiple ways. The overriding principle is addressing the etiology of the joint line elevation. Typically, over-resection of the distal and posterior femoral condyle leads to an increased tibial polyethylene insert. Revision of the components to a larger femoral implant with distal and posterior augments can correct this problem.

### Treatment and Outcomes

Historically, treatments for knee stiffness resultant from patella baja were described in native knees. Typically, from previous knee surgery such as ACL reconstruction, initial treatments such as adhesion, scar, and capsular débridement failed to improve knee range of motion if the arthrofibrosis was accompanied with patella baja. Paulos et al<sup>39</sup> described their treatment of early intra-articular and extra-articular capsular débridement and release for patellar stiffness. They concluded patients with patella baja did not improve with simple débridement, suggesting additional procedures may be needed to improve the patellar location.

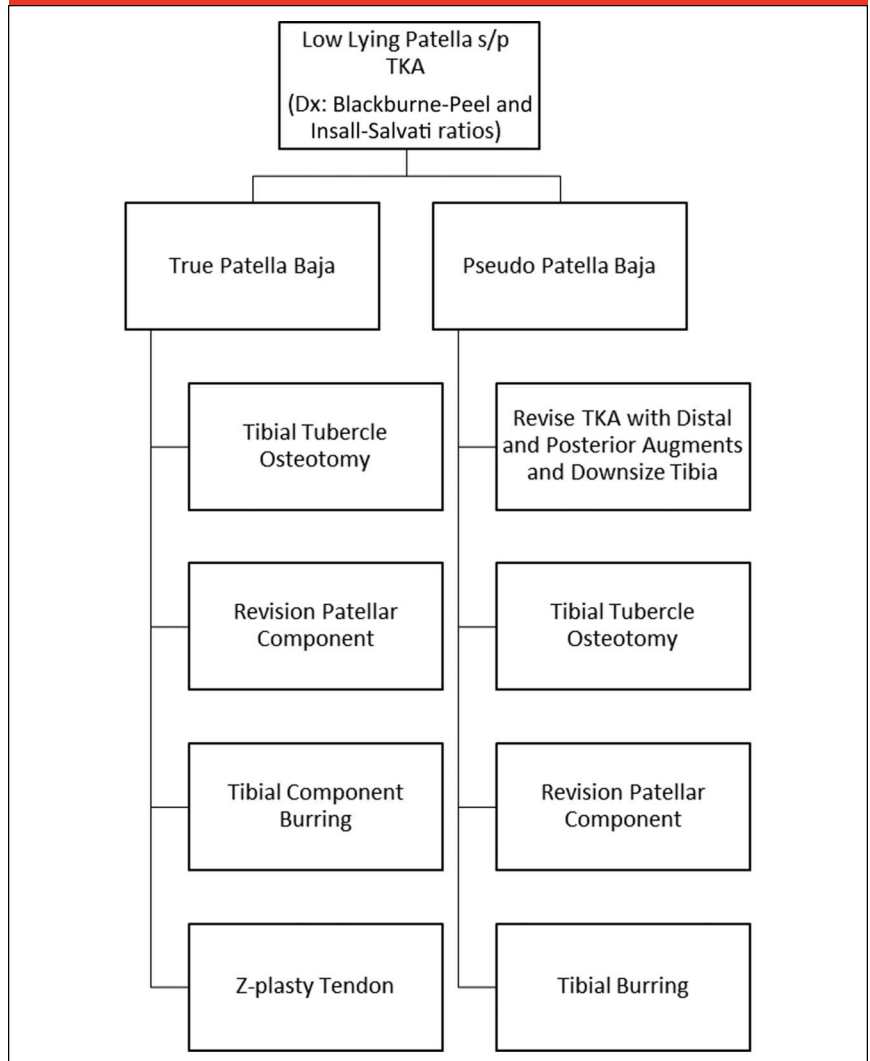
This led to other surgical options for patella baja in the native knee. Some literature described tendon Z-plasty resulting in significant improvement.<sup>40,41</sup> Dejour et al in Lyon, France, described 35 patients who had previous surgeries or injuries to the knee within an average Insall ratio of 0.55 (range, 0.35 to 0.87). Their surgical technique entailed isolation of the patellar tendon, a single longitudinal incision down the center from patellar pole to tibial tubercle with each short arm of the Z transecting superiorly on one end and inferiorly on the other. The tendon was subsequently lengthened and sutured together by each adjacent arm. Postoperatively, Insall ratio increased to 1.02, with 26 patients having an excellent or good result and 9 patients having poor results. They concluded low ratios <0.6 had better predictability of a good outcome. Wierer et al similarly reported on four patients with patella baja (Caton-Dechamps ratio, 0.53) from previous surgeries, treated with a modified four limb Z-plasty. Using a similar exposure as Dejour et al, they created two additional limbs of the Z-plasty to a total of four by transecting the two transverse limbs in a coronal plane anteriorly to posteriorly. Although this creates thinner limbs, it allows more surface overlap at the lengthened site and possibly more strength. At 34-month follow-up, the Lysholm score improved from 49 to 91. They concluded modified Z-plasty may be a valuable treatment of patella baja. Of note, these procedures were done in native knees without a total knee prosthesis. To date, there has been no record of Z-plasty in the setting of previous TKA. Likely due to the concern of extensor mechanism failure, many arthroplasty surgeons avoid intentional incision at the patellar tendon.

Vives-Barquiel et al<sup>42</sup> examined patella baja specifically in TKA knees and demonstrated that proximal

osteotomy of the tibial tuberosity was a successful treatment which improved flexion by an average of 30° and improved clinical outcome scores. They reported on 21 patients with poor functioning TKA with patella baja, average Blackburne-Peel ratio 0.3, flexion 70°, and Western Ontario and McMaster Universities Osteoarthritis Index outcome scores of pain 14 and function 42. Intraoperatively, after doing an open lysis of adhesions and synovectomy, a tibial tubercle osteotomy of 4 to 6 cm in length and 1 cm in depth was done, moved proximally by 1.5 cm and fixed with two 1.6-mm wire cerclages. Patellar tracking was then assessed. If the patella was not resurfaced, it was done at this time. At an average follow-up of 35 months, flexion improved to 100°, Western Ontario and McMaster Universities Osteoarthritis Index pain improved to 9, and function improved to 20. Blackburne-Peel ratio averaged 0.5. Complications included acute infection treated with débridement, polyethylene exchange and antibiotic treatment (two patients, 9.5%), wound dehiscence that required débridement and reclosure (one patient), aseptic loosening unrelated to the osteotomy requiring revision (two patients), and asymptomatic non-union of the osteotomy with full active extension and no functional deficits (three patients, 15%). Although patients demonstrated significant ( $P < 0.01$ ) improvement in patellar height, ROM, pain, function, and satisfaction, there were notable complications similar to revision TKA surgery.

Vandeputte and Vandenneucker<sup>43</sup> reported similar success with fewer complications in patients with pseudopatella baja in TKA who were undergoing revision TKA. They compared 13 patients undergoing TKA revision with proximal tibial tubercle osteotomy to a matched cohort of 13 undergoing TKA revision without proximalization. Both cohorts were matched by age, sex,

Figure 5



Treatment decision process. After identification of possible patella baja on lateral radiograph, treatment options are listed below for true patella baja or pseudopatella baja. Femoral revision should be considered with pseudopatella baja due to notable joint line elevate. TKA = total knee arthroplasty

body mass index, surgical time, and radiographic patellar height. Intraoperatively, their osteotomy consisted of 6 to 8 cm length by 1 to 2 cm width, and preservation of the lateral muscle and periosteal attachments, with bony stabilization with screws or cerclage wires. The knee was taken through an ROM with final fixation before closure. At 2-year follow-up, the osteotomy group had markedly more improvement compared with the control

group, with proximalization of the tubercle more than 1 cm reporting the better improvements. They had no nonunions nor extensor lags.

Several authors described additional methods to prevent patellar impingement and subsequent loss of ROM in patella baja in TKA.<sup>8,44,45</sup> They have done anterior tibial polyethylene burring to allow the patella to sit in an anterior recess, preventing impingement of the patella. In addition, revision of the patellar component to a

superior location if it was placed too inferiorly resulting in impingement was also described.<sup>45,46</sup> Unfortunately, no author reported outcomes strictly for these procedures. They also acknowledged tibial tubercle proximalization or patellar tendon lengthening as treatments for patellar tendon contracture.

Although we have listed the reported treatment options for treatment of patella baja or pseudopatella baja after TKA, there is a paucity of literature on this topic. Additional research is warranted. Ultimately, addressing the underlying etiology is a good guide to success (Figure 5).

### Summary

Patella baja and pseudopatella baja are common complications after TKA. This may be due to anatomical, biomechanical, and surgical etiologies. Regardless, pseudopatella baja and patella baja result in worse functional and patient-reported outcomes after TKA. Making the correct diagnosis and differentiating patella baja from pseudopatella baja is critical to determine etiology and appropriate management. Treatment may consist of tibial tubercle proximal osteotomy, tendon Z-plasty, tibial component burring, patellar revision, femoral revision or all component revision; however, additional research is needed before an optimal algorithm can be constructed.

### References

References printed in **bold type** are those published within the past 5 years.

1. Hughston JC, Walsh WM: Proximal and distal reconstruction of the extensor mechanism for patellar subluxation. *Clin Orthop Relat Res* 1979;36-42.
2. Wiesel SW: *Operative Techniques in Orthopaedic Surgery*. Philadelphia, PA, Lippincott Williams & Wilkins, 2012.
3. Flören M, Davis J, Peterson MG, Laskin RS: A mini-midvastus capsular approach

- with patellar displacement decreases the prevalence of patella baja. *J Arthroplasty* 2007;22:51-57.
4. Fox AJ, Wanivenhaus F, Rodeo SA: The basic science of the patella: Structure, composition, and function. *J Knee Surg* 2012;25:127-142.
5. Blazina ME, Fox JM, Carlson AJ, Jurgutis JJ: Patella baja. *J Bone Joint Surg* 1975; 57A:1027.
6. Lancourt JE, Cristini JA: Patella alta and patella infera: Their etiological role in patellar dislocation, chondromalacia, and apophysitis of the tibial tubercle. *J Bone Joint Surg Am* 1975;57:1112-1115.
7. Cameron HU, Jung YB: Patella baja complicating total knee arthroplasty: A report of two cases. *J Arthroplasty* 1988;3: 177-180.
8. Chonko DJ, Lombardi AV Jr, Berend KR: Patella baja and total knee arthroplasty (TKA): Etiology, diagnosis, and management. *Surg Technol Int* 2004;12: 231-238.
9. Ahmad CS, Kwak SD, Ateshian GA, Warden WH, Steadman JR, Mow VC: Effects of patellar tendon adhesion to the anterior tibia on knee mechanics. *Am J Sports Med* 1998;26:715-724.
10. Mariani PP, Del Signore S, Perugia L: Early development of patella infera after knee fractures. *Knee Surg Sports Traumatol Arthrosc* 1994;2:166-169.
11. Paulos LE, Wnorowski DC, Greenwald AE: Infrapatellar contracture syndrome: Diagnosis, treatment, and long-term followup. *Am J Sports Med* 1994;22: 440-449.
12. Krieg JC, Mirza A: Case report: Patella baja after retrograde femoral nail insertion. *Clin Orthop Relat Res* 2008;467:566-571.
13. Tria AJ Jr, Alicea JA, Cody RP: Patella baja in anterior cruciate ligament reconstruction of the knee. *Clin Orthop Relat Res* 1994: 229-234.
14. Portner O: High tibial valgus osteotomy: Closing, opening or combined? Patellar height as a determining factor. *Clin Orthop Relat Res* 2014;472:3432-3440.
15. Weale AE, Murray DW, Newman JH, Ackroyd CE: The length of the patellar tendon after unicompartmental and total knee replacement. *J Bone Joint Surg Br* 1999;81:790-795.
16. **Davies GS, van Duren B, Shorthose M, et al: Changes in patella tendon length over 5 years after different types of knee arthroplasty. *Knee Surg Sports Traumatol Arthrosc* 2016;24:3029-3035.**
17. Noyes FR, Wojtys EM, Marshall MT: The early diagnosis and treatment of developmental patella infera syndrome. *Clin Orthop Relat Res* 1991:241-252.

18. **White L, Holyoak R, Sant J, Hartnell N, Mullan J: The effect of infrapatellar fat pad resection on outcomes post-total knee arthroplasty: A systematic review. *Arch Orthop Trauma Surg* 2016;136:701-708.**
19. Thorpe CD, Bocell JR, Tullos HS: Intra-articular fibrous bands: Patellar complications after total knee replacement. *J Bone Joint Surg Am* 1990;72:811-814.
20. Gromov K, Korchi M, Thomsen MG, Husted H, Troelsen A: What is the optimal alignment of the tibial and femoral components in knee arthroplasty? An overview of the literature. *Acta Orthop* 2014;85:480-487.
21. Kazemi SM, Besheli LD, Ejazi A, et al: Pseudo-patella baja after total knee arthroplasty. *Med Sci Monit* 2011;17: CR292-CR296.
22. Grelsamer RP: Patella baja after total knee arthroplasty: Is it really patella baja? *J Arthroplasty* 2002;17:66-69.
23. **Bugelli G, Ascione F, Cazzella N, et al: Pseudo-patella baja: A minor yet frequent complication of total knee arthroplasty. *Knee Surg Sports Traumatol Arthrosc* 2018;26:1831-1837.**
24. Sharma V, Tsailas PG, Maheshwari AV, Ranawat AS, Ranawat CS: Does patellar eversion in total knee arthroplasty cause patella baja? *Clin Orthop Relat Res* 2008; 466:2763-2768.
25. Kayler DE, Lyttle D: Surgical interruption of patellar blood supply by total knee arthroplasty. *Clin Orthop Relat Res* 1988: 221-227.
26. Anagnostakos K, Lorbach O, Kohn D: Patella baja after unicompartmental knee arthroplasty. *Knee Surg Sports Traumatol Arthrosc* 2012;20:1456-1462.
27. Blumensaat C: *Die lageabweichungen und verrenkungen der kniescheibe. In: Ergebnisse der Chirurgie und Orthopädie 1938*. Berlin, Heidelberg, Springer, 149-223.
28. Insall J, Salvati E: Patella position in the normal knee joint. *Radiology* 1971;101: 101-104.
29. Meneghini RM, Ritter MA, Pierson JL, Meding JB, Berend ME, Faris PM: The effect of the Insall-Salvati ratio on outcome after total knee arthroplasty. *J Arthroplasty* 2006;21(6 suppl 2): 116-120.
30. Grelsamer RP, Meadows S: The modified Insall-Salvati ratio for assessment of patellar height. *Clin Orthop Relat Res* 1992:170-176.
31. Blackburne JS, Peel TE: A new method of measuring patellar height. *J Bone Joint Surg Br* 1977;592:241-242.
32. **Behrend H, Graulich T, Gerlach R, Spross C, Ladurner A: Blackburne-Peel ratio predicts patients' outcomes after total knee**



- arthroplasty. *Knee Surg Sports Traumatol Arthrosc* 2019;27:1562-1569.
33. Caton J, Deschamps G, Chambat P, Lerat JL, Dejour H: Patella infera. Apropos of 128 cases [French]. *Rev Chir Orthop Reparatrice Appar Mot* 1982;68:317-325.
  34. Portner O, Pakzad H: The evaluation of patellar height: A simple method. *J Bone Joint Surg Am* 2011;93:73-80.
  35. Cabral F, Sousa-Pinto B, Pinto R, Torres J: Patellar height after total knee arthroplasty: Comparison of 3 methods. *J Arthroplasty* 2017;32:552-557.e2.
  36. Thornton-Bott P, Unitt L, Johnstone DJ, Sambatakakis A: Pseudo-patella baja following soft tissue balancing in total knee arthroplasty. *Ann R Coll Surg Engl* 2005; 87:484.
  37. Havet E, Gabrion A, Leiber-Wackenheim F, Vernois J, Olory B, Mertl P: Radiological study of the knee joint line position measured from the fibular head and proximal tibial landmarks. *Surg Radiol Anat* 2007;29:285-289.
  38. Pereira GC, Von Kaeppler E, Alaia MJ, et al: Calculating the position of the joint line of the knee using anatomical landmarks. *Orthopedics* 2016;39:381-386.
  39. Paulos LE, Rosenberg TD, Drawbert J, Manning J, Abbott P: Infrapatellar contracture syndrome: An unrecognized cause of knee stiffness with patella entrapment and patella infera. *Am J Sports Med* 1987;15:331-341.
  40. Dejour D, Levigne C, Dejour H: Postoperative low patella: Treatment by lengthening of the patellar tendon. *Rev Chir Orthop Reparatrice Appar Mot* 1995;81:286-295.
  41. Wierer G, Hoser C, Herbst E, Abermann E, Fink C: Treatment of patella baja by a modified Z-plasty. *Knee Surg Sports Traumatol Arthrosc* 2016;24:2943-2947.
  42. Vives-Barquiel MA, Torrents A, Lozano L, et al: Proximalize osteotomy of tibial tuberosity (POTT) as a treatment for stiffness secondary to patella baja in total knee arthroplasty (TKA). *Arch Orthop Trauma Surg* 2015;135:1445-1451.
  43. Vandeputte FJ, Vandenneucker H: Proximalisation of the tibial tubercle gives a good outcome in patients undergoing revision total knee arthroplasty who have pseudo patella baja. *Bone Joint J* 2017;99-B:912-916.
  44. Argenson JN, Scuderi GR, Komistek RD, Scott WN, Kelly MA, Aubaniac JM: In vivo kinematic evaluation and design considerations related to high flexion in total knee arthroplasty. *J Biomech* 2005;38: 277-284.
  45. Grigoris PH, Treacy RB, McMinn DJ: Patellotibial impingement in Kinemax stabilised total knee replacement. *J Bone Joint Surg Br* 1992;74:472-473.
  46. Maeno S, Kondo M, Niki Y, Matsumoto H: Patellar impingement against the tibial component after total knee arthroplasty. *Clin Orthop Relat Res* 2006;452:265-269.