

Case Report

Septic shock induced by *Lecythophora mutabilis* in a patient with mitochondrial encephalomyopathy

Yuki Taniguchi,¹ Takeshi Taketani,^{2,3} Hidehiko Moriyama,¹ Shoji Moriki,¹ Kazuko Nishimura,⁴ Emi Sato,¹ Yasuko Notsu,¹ Tsuyoshi Higuchi,³ Yuichiro Sugitani,³ Kenji Yasuda,³ Atsushi Nagai,⁵ Seiji Yamaguchi,³ Hiroshi Shibata¹ and Junichi Masuda⁵

Correspondence

Takeshi Taketani

ttaketani@med.shimane-u.ac.jp

¹Central Clinical Laboratory, Shimane University Hospital, Shimane, Japan

²Division of Blood Transfusion, Shimane University Hospital, Shimane, Japan

³Department of Pediatrics, Shimane University School of Medicine, Shimane, Japan

⁴Medical Mycology Research Center, Chiba University, Chiba, Japan

⁵Department of Laboratory Medicine, Shimane University School of Medicine, Shimane, Japan

Received 24 February 2009

Accepted 3 June 2009

Invasive fungal infection (IFI) caused by *Lecythophora mutabilis* occasionally occurs in patients with impaired host immunity; such patients had eosinophilia at onset, and surviving patients were treated with fungal cell-membrane-targeted drugs. An 18-year-old man with mitochondrial encephalomyopathy accompanied with refractory anaemia and chronic renal failure developed septic shock caused by *L. mutabilis*, which was detected from a blood culture, and was identified morphologically and genetically. During the course of the infection, he had eosinophilia, although β -D-glucan levels were within the normal range. He was treated with micafungin, but deteriorated and died, despite his treatment being changed to liposomal amphotericin B. On the basis of this we suggest that IFI caused by *L. mutabilis* should be suspected when a compromised host develops infection and eosinophilia, and that antifungal drugs that target β -D-glucan are not advisable.

Introduction

Marked advances in medical science and healthcare, especially the progress of anti-cancer drugs for treating patients with malignancies, immunosuppressant drugs for those with autoimmune disorders, and haematopoietic or organ transplantations, have resulted in the improvement of individual and familial quality of life. However, these treatments sometimes induce decreased host immunity, and consequently the incidence of opportunistic infection, notably fungal infections, has increased (Revankar *et al.*, 2002; Brandt & Warnock, 2003; Lai *et al.*, 2008). The problems of dealing with fungal infections include difficulties in performing early and precise diagnosis, and subsequent appropriate antifungal therapy with relatively fewer side effects compared to antibacterial agents (Lai *et al.*, 2008). As a result, patients with fungal infection have a high mortality rate (Lai *et al.*, 2008).

Among infections in humans caused by pathogenic moulds, phaeohyphomycosis is a rare infection caused by dematiaceous fungi, which are widely distributed in the

environment and are characterized by the presence of melanin or melanin-like pigments in the cell walls of their hyphae, conidia or both (Revankar *et al.*, 2002; Brandt & Warnock, 2003). More patients are becoming infected by these fungi as the number of immunocompromised people has continued to increase. Herein we describe a case of septic shock caused by a dematiaceous fungus, *Lecythophora mutabilis*, in a patient with mitochondrial encephalomyopathy.

Case report

An 18-year-old man was admitted to Shimane University Hospital because he received antibiotics for aspiration pneumonia. He had been suffering from mitochondrial encephalomyopathy since he was 3 years old, and was bedridden and on a mechanical respirator due to the advanced state of his original disease. He had two complications: transfusion-dependent refractory anaemia and chronic renal failure that was being treated with peritoneal dialysis. Two weeks after admission, his aspiration pneumonia improved, but he presented with watery diarrhoea, without a fever. The diarrhoea gradually worsened, and his C-reactive protein (CRP) concentration was elevated (146 mg l^{-1}), although his white blood cell

Abbreviations: AMB, amphotericin B; CRP, C-reactive protein; IFI, invasive fungal infection; L-AMB, liposomal amphotericin B; MCFG, micafungin; MRSA, methicillin-resistant *Staphylococcus aureus*; VCM, vancomycin.

count was 5500 cells μl^{-1} , with 45% neutrophils, 13% eosinophils, 21% monocytes and 21% lymphocytes. At this time, his β -D-glucan level was 10.4 pg ml^{-1} (normal value <11.0 pg ml^{-1}). Meticillin-resistant *Staphylococcus aureus* (MRSA), but not *Clostridium difficile*, was detected from his stool culture. Neither oocysts nor parasites were found in faecal samples, nor were viruses. He was diagnosed with MRSA enteritis, and his symptoms and clinical characteristics improved after treatment with oral vancomycin (VCM) (Fig. 1). One week after the initiation of VCM therapy, a yeast-like fungus grew in a blood culture from a sample collected on the day the treatment for MRSA enteritis commenced. The shape of this fungus was similar to *Trichosporon* (Fig. 2), but we could not identify this fungus as *L. mutabilis*. Antifungal therapy [micafungin (MCFG) 5 mg kg^{-1} per day] was started, although the patient's β -D-glucan level was within the normal range (8.7 pg ml^{-1}) and no fungus was detected in his blood at this point (Fig. 1). He presented with no symptoms, but his CRP level slowly elevated again. Seven days after treatment with MCFG, deterioration of consciousness, bradycardia, hypotension and oxygen desaturation suddenly occurred, and leukocytosis (15 290 μl^{-1}) and an elevated CRP level (165 mg l^{-1}) were recognized, and a chest X-ray showed a consolidation shadow on the right upper lobe of the lung. X-ray and computed tomography examinations of the gut indicated that a perforation was unlikely. His β -D-glucan level was still within the normal range (9.0 pg ml^{-1}). He was diagnosed with septic shock due to bacterial pneumonia. In spite of intensive therapy, including antibacterial therapy (linezolid and ciprofloxacin, and γ -globulin), cardiovascular agents and respiratory management, his condition worsened. Considering that the pathogen was likely to be a fungus, because antibacterial treatment was not effective, 3 days after the septic shock

was diagnosed we changed his treatment from MCFG to liposomal amphotericin B (L-AMB) (3 mg kg^{-1} per day), and his β -D-glucan level fell to less than the detection value 3 days after treatment with L-AMB; however, his condition deteriorated and he died due to multiple organ failure. Later, a yeast-like fungus, which was the same as that detected previously, was found in a blood culture collected on the day of septic shock, strongly suggesting that the cause of septic shock was the fungus.

The detected fungus was grown at 37 °C in liquid culture that included trypticase soy broth with peptone, brain heart infusion bouillon and activated carbon (Fig. 2a). By subculturing the fungus at 25 °C for 22 days on potato dextrose agar (PDA) and Sabouraud dextrose agar (SDA) media giant colonies formed on both media (Fig. 2b). The colony on PDA medium was cream-coloured with toroidal pale-brown pigmentation, and the colony on SDA medium became salmon-coloured with central brown pigmentation (Fig. 2b). For identification at the species level, slide cultures were made using giant colonies to observe the relative arrangement of conidia and conidia-bearing structures. Slide cultures revealed that this fungus had bottle-shaped or urceolate conidia-producing cells, phialides, and produced elliptical conidia and brown chlamydospores with smoothly shaped walls (Fig. 2c). The basal septum of phialides was absent (Fig. 2c). These results demonstrated that the fungus was likely to be a dematiaceous fungus, *L. mutabilis*. To confirm the diagnosis genetically, we extracted DNA from the fungus and determined the base sequence of large subunit (26S) rRNA-encoding gene (LSUrRNA) D1/D2 domain of *L. mutabilis* (Abliz *et al.*, 2004). The isolated base sequence of the D1/D2 domain of LSurRNA from *L. mutabilis* had complete homology to that (GenBank accession number AF353604.1) of *L. mutabilis* isolated in the past (data not

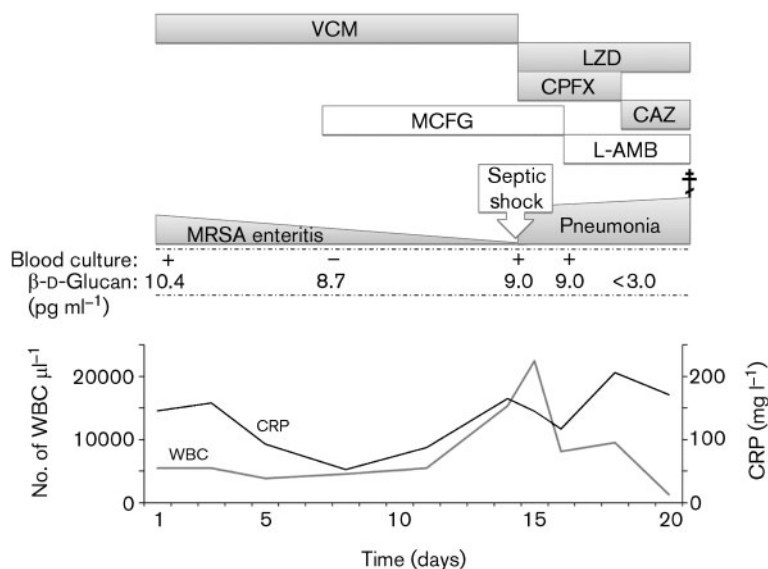


Fig. 1. Clinical course of the infection. CAZ, Cefazidime; CPF, ciprofloxacin; LZD, linezolid; WBC, white blood cell.

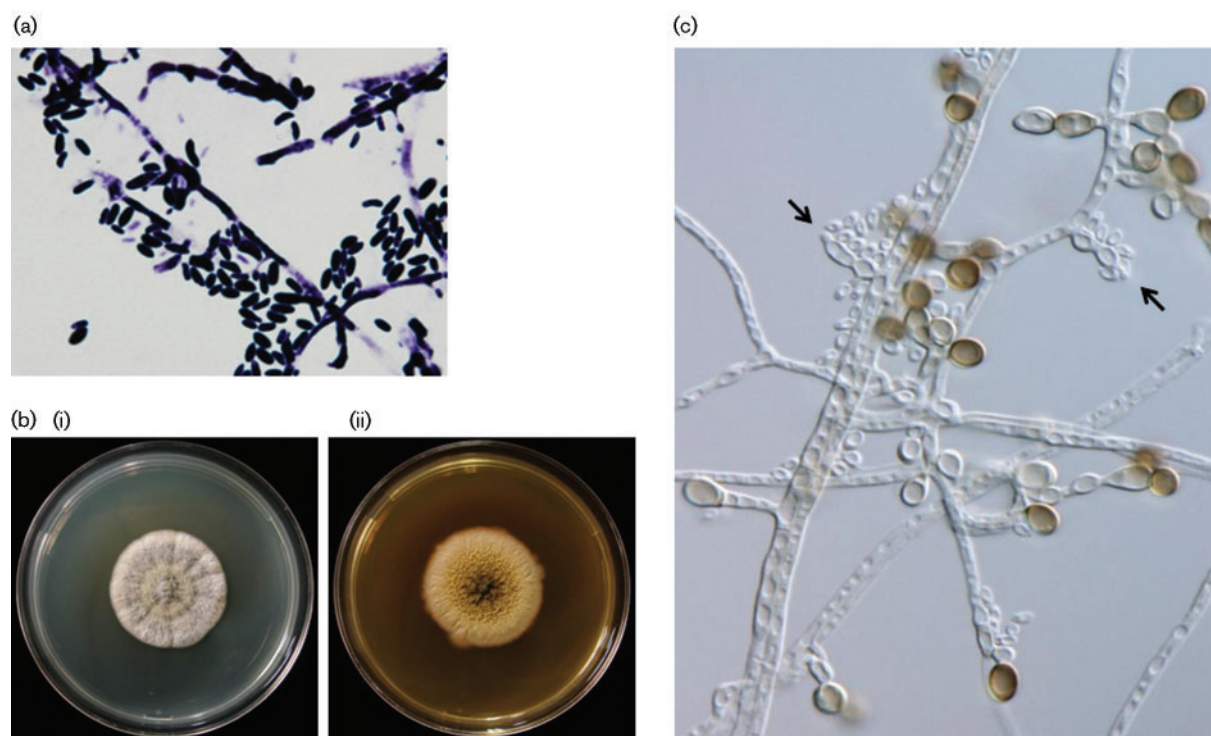


Fig. 2. *L. mutabilis* detected in blood culture. (a) Gram staining, magnification $\times 400$. (b) Giant colonies of *L. mutabilis* on: (i) potato dextrose agar medium; (ii) SDA medium. (c) Morphological characteristics of *L. mutabilis* detected by slide culture. Arrows indicate phialides producing many conidia.

shown). As a result, we could genetically identify the fungus as *L. mutabilis*. In addition, we examined the susceptibility of *L. mutabilis* to antifungal agents *in vitro*. At 48 h the fungal cells were sensitive to AMB (MIC $0.25 \mu\text{g ml}^{-1}$), flucytosine (MIC $0.25 \mu\text{g ml}^{-1}$), itraconazole (MIC $0.01 \mu\text{g ml}^{-1}$), miconazole (MIC $0.06 \mu\text{g ml}^{-1}$) and voriconazole (MIC $0.06 \mu\text{g ml}^{-1}$), but resistant to fluconazole (MIC $4 \mu\text{g ml}^{-1}$) and MCFG (MIC $8 \mu\text{g ml}^{-1}$).

Discussion

L. mutabilis, a dematiaceous fungus, is reported to be a rare pathogen with regards to human infection (Revankar *et al.*, 2002; Lai *et al.*, 2008) and only eight patients have been reported (Pierach *et al.*, 1973; Slifkin & Bowers, 1975; Ahmad *et al.*, 1985; Pritchard & Muir, 1987; Ho *et al.*, 1991; Marcus *et al.*, 1999; Scott *et al.*, 2004; Drees *et al.*, 2007). The age of the patients at diagnosis was a mean of 49 years old (range 25–61 years old). Infection with *L. mutabilis* consisted of two disorder groups: invasive fungal infection (IFI) and ocular disease. Regarding four patients with IFIs reported elsewhere, three were diagnosed with endocarditis and one with peritonitis (Pierach *et al.*, 1973; Slifkin & Bowers, 1975; Ahmad *et al.*, 1985; Drees *et al.*, 2007). Three (75 %) of the four patients had IFI based on impaired host immunity, including rheumatic fever, diabetes mellitus and polycystic kidney with continuous

ambulatory peritoneal dialysis (Slifkin & Bowers, 1975; Ahmad *et al.*, 1985; Drees *et al.*, 2007). Three (75 %) of the four patients presented with eosinophilia (Pierach *et al.*, 1973; Slifkin & Bowers, 1975; Drees *et al.*, 2007). Eosinophilia was also found in 11 % of infections caused by dematiaceous fungi, although it was unclear why eosinophilia occurred (Revankar *et al.*, 2002). *L. mutabilis* was detected in valve vegetation in patients with endocarditis, and in peritoneal fluid in a patient with peritonitis; however, no *L. mutabilis* was detected from the blood of patients with IFIs (Pierach *et al.*, 1973; Slifkin & Bowers, 1975; Ahmad *et al.*, 1985; Drees *et al.*, 2007). Two (50 %) of the four patients with IFI died without receiving antifungal therapy (Pierach *et al.*, 1973; Slifkin & Bowers, 1975). The other two survivors required long-term antifungal treatment of 38 weeks and more than 2 years, respectively (Ahmad *et al.*, 1985; Drees *et al.*, 2007). Our patient was diagnosed with septic shock caused by *L. mutabilis*, which was detected from his blood. His host immunity was decreased due to refractory anaemia and chronic renal failure; he also had eosinophilia. Our case is believed to be the first report of septic shock from *L. mutabilis*, which was confirmed by the detection of *L. mutabilis* from blood culture. He died although antifungal treatment was started 1 week after the detection of *L. mutabilis* in his blood. These results suggest that rare IFIs caused by *L. mutabilis* should be suspected when the compromised host develops

infections with eosinophilia, and might resolve if early and appropriate antifungal treatment is provided.

Early and accurate diagnosis of IFI is difficult; therefore, patients with IFI have a high mortality rate (Lai *et al.*, 2008). In blood culture and histopathological examinations, it takes a long time to identify the mould, and the sensitivity and specificity of the tests are insufficient (Yeo & Wong, 2002; Lai *et al.*, 2008). We also required 1 week to confirm the fungus in blood culture and it could not be detected when we re-examined the blood culture before commencing antifungal treatment. Recently, various detection methods have been developed with representative methods including the detection of: fungal cell-wall components (galactomannan and β -D-glucan), fungal DNA by PCR, and distinctive fungal metabolites (D-arabinitol and mannitol) (Yeo & Wong, 2002). When we serially measured β -D-glucan, all measured samples were within the normal range (<11.0 pg ml⁻¹); however, interestingly, β -D-glucan decreased to below the detection range after we changed the treatment from MCFG to L-AMB. MCFG has an antifungal action that inhibits the synthesis of β -D-glucan, while L-AMB binds to ergosterol, part of the fungal cell membrane, resulting in increased permeability of the fungal membrane, and induces cell death. Detection of β -D-glucan is useful for detecting *Candida*, *Aspergillus* and *Fusarium* spp., but not zygomycetes and *Cryptococcus*, which contain little or no β -D-glucan (Yeo & Wong, 2002; Lai *et al.*, 2008). β -D-Glucan has never been measured in patients with IFI from *L. mutabilis*, and there are no reports on whether or not *L. mutabilis* contains β -D-glucan; however, the decline of β -D-glucan levels in our patient suggested that *L. mutabilis* might contain little β -D-glucan. A fungal susceptibility test indicated that *L. mutabilis* was resistant to MCFG in our study. Two surviving patients with IFI from *L. mutabilis* received a combination of AMB lipid complex and voriconazole, and miconazole and ketoconazole (Ahmad *et al.*, 1985; Drees *et al.*, 2007). We administered MCFG, an antifungal with relatively few side effects, prior to the identification of this fungus as *L. mutabilis*, as the patient had chronic renal failure. However, our patient deteriorated during treatment with MCFG,

suggesting that it is inadvisable to use antifungal drugs that target β -D-glucan when *L. mutabilis* infection occurs.

References

- Abliz, P., Fukushima, K., Takizawa, K. & Nishimura, K. (2004). Identification of pathogenic dematiaceous fungi and related taxa based on large subunit ribosomal DNA D1/D2 domain sequence analysis. *FEMS Immunol Med Microbiol* **40**, 41–49.
- Ahmad, S., Johnson, R. J., Hillier, S., Shelton, W. R. & Rinaldi, M. G. (1985). Fungal peritonitis caused by *Lecythrphora mutabilis*. *J Clin Microbiol* **22**, 182–186.
- Brandt, M. E. & Warnock, D. W. (2003). Epidemiology, clinical manifestations, and therapy of infections caused by dematiaceous fungi. *J Chemother* **15** (Suppl. 2), 36–47.
- Drees, M., Wickes, B. L., Gupta, M. & Hadley, S. (2007). *Lecythrphora mutabilis* prosthetic valve endocarditis in a diabetic patient. *Med Mycol* **45**, 463–467.
- Ho, R. H., Bernard, P. J. & McClellan, K. A. (1991). *Phialophora mutabilis* keratomycosis. *Am J Ophthalmol* **112**, 728–729.
- Lai, C. C., Tan, C. K., Huang, Y. T., Shao, P. L. & Hsueh, P. R. (2008). Current challenges in the management of invasive fungal infections. *J Infect Chemother* **14**, 77–85.
- Marcus, D. M., Hull, D. S., Rubin, R. M. & Newman, C. L. (1999). *Lecythrphora mutabilis* endophthalmitis after long-term corneal cyanoacrylate. *Retina* **19**, 351–353.
- Pierach, C. A., Gülmen, G., Dhar, G. J. & Kiser, J. C. (1973). Letter: *Phialophora mutabilis* endocarditis. *Ann Intern Med* **79**, 900–901.
- Pritchard, R. C. & Muir, D. B. (1987). Black fungi: a survey of dematiaceous hyphomycetes from clinical specimens identified over a five year period in a reference laboratory. *Pathology* **19**, 281–284.
- Revankar, S. G., Patterson, J. E., Sutton, D. A., Pullen, R. & Rinaldi, M. G. (2002). Disseminated phaeohyphomycosis: review of an emerging mycosis. *Clin Infect Dis* **34**, 467–476.
- Scott, I. U., Cruz-Villegas, V., Flynn, H. W., Jr & Miller, D. (2004). Delayed-onset, bleb-associated endophthalmitis caused by *Lecythrphora mutabilis*. *Am J Ophthalmol* **137**, 583–585.
- Slifkin, M. & Bowers, H. M., Jr (1975). *Phialophora mutabilis* endocarditis. *Am J Clin Pathol* **63**, 120–130.
- Yeo, S. F. & Wong, B. (2002). Current status of nonculture methods for diagnosis of invasive fungal infections. *Clin Microbiol Rev* **15**, 465–484.